



## ORIGINAL ARTICLE

# Treatment of invasive fungal diseases in cancer patients— Revised 2019 Recommendations of the Infectious Diseases Working Party (AGIHO) of the German Society of Hematology and Oncology (DGHO)

Markus Ruhnke<sup>1</sup>  | Oliver A. Cornely<sup>2,3,4,5</sup>  | Martin Schmidt-Hieber<sup>6</sup> | Nael Alakel<sup>7</sup> |  
Boris Boell<sup>2</sup> | Dieter Buchheidt<sup>8</sup> | Maximilian Christopeit<sup>9</sup> | Justin Hasenkamp<sup>10</sup> |  
Werner J. Heinz<sup>11</sup>  | Marcus Hentrich<sup>12</sup> | Meinolf Karthaus<sup>13</sup> | Michael Koldehoff<sup>14</sup> |  
Georg Maschmeyer<sup>15</sup> | Jens Panse<sup>16</sup> | Olaf Penack<sup>17</sup> | Jan Schleicher<sup>18</sup> |  
Daniel Teschner<sup>19</sup> | Andrew John Ullmann<sup>20</sup> | Maria Vehreschild<sup>2,3,21,22</sup> |  
Marie von Lilienfeld-Toal<sup>23</sup> | Florian Weissinger<sup>1</sup> | Stefan Schwartz<sup>24</sup>

<sup>1</sup>Division of Haematology, Oncology and Palliative Care, Department of Internal Medicine, Evangelisches Klinikum Bethel, Bielefeld, Germany

<sup>2</sup>Department I of Internal Medicine, Faculty of Medicine, University of Cologne, Cologne, Germany

<sup>3</sup>ECMM Excellence Centre of Medical Mycology, Cologne, Germany

<sup>4</sup>Cologne Excellence Cluster on Cellular Stress Responses in Aging-Associated Diseases (CECAD), University of Cologne, Cologne, Germany

<sup>5</sup>Clinical Trials Centre Cologne (ZKS Köln), University of Cologne, Cologne, Germany

<sup>6</sup>Klinik für Hämatologie und Onkologie, Carl-Thiem Klinikum, Cottbus, Germany

<sup>7</sup>Department I of Internal Medicine, Haematology and Oncology, University Hospital Dresden, Dresden, Germany

<sup>8</sup>Department of Hematology and Oncology, Mannheim University Hospital, Heidelberg University, Mannheim, Germany

<sup>9</sup>Department of Stem Cell Transplantation & Oncology, University Medical Center Eppendorf, Hamburg, Germany

<sup>10</sup>Clinic for Haematology and Medical Oncology with Department for Stem Cell Transplantation, University Medicine Göttingen, Göttingen, Germany

<sup>11</sup>Schwerpunkt Infektiologie, Medizinische Klinik und Poliklinik II, Universitätsklinikum Würzburg, Würzburg, Germany

<sup>12</sup>Hämatologie und Internistische Onkologie, Innere Medizin III, Rotkreuzklinikum München, München, Germany

<sup>13</sup>Department of Haematology & Oncology, Municipal Hospital Neuperlach, München, Germany

<sup>14</sup>Klinik für Knochenmarktransplantation, Westdeutsches Tumorzentrum Essen, Universitätsklinikum Essen (AöR), Essen, Germany

<sup>15</sup>Department of Hematology, Oncology and Palliative Care, Klinikum Ernst von Bergmann, Potsdam, Germany

<sup>16</sup>Klinik für Onkologie, Hämatologie und Stammzelltransplantation, Universitätsklinikum Aachen, Aachen, Germany

<sup>17</sup>Division of Haematology & Oncology, Department of Internal Medicine, Charité University Medicine, Campus Rudolf Virchow, Berlin, Germany

<sup>18</sup>Klinik für Hämatologie Onkologie und Palliativmedizin, Katharinenhospital, Stuttgart, Germany

<sup>19</sup>III. Medizinische Klinik und Poliklinik, Universitätsmedizin der Johannes Gutenberg-Universität Mainz, Mainz, Germany

<sup>20</sup>Department of Internal Medicine II, Julius Maximilians University, Würzburg, Germany

<sup>21</sup>Zentrum für Innere Medizin, Infektiologie, Goethe Universität Frankfurt, Frankfurt am Main, Deutschland

<sup>22</sup>Deutsches Zentrum für Infektionsforschung (DZIF), Standort Bonn-Köln, Deutschland

<sup>23</sup>Klinik für Innere Medizin II, Abteilung für Hämatologie und Internistische Onkologie, Universitätsklinikum Jena, Jena, Germany

<sup>24</sup>Division of Haematology & Oncology, Department of Internal Medicine, Charité University Medicine, Campus Benjamin Franklin, Berlin, Germany

[Correction added on 24 May 2021, after first online publication: Author name Georg Maschmeyer was previously incorrect and has been corrected in this current version.]

This is an open access article under the terms of the Creative Commons Attribution License, which permits use, distribution and reproduction in any medium, provided the original work is properly cited.

© 2020 The Authors. *Mycoses* published by Blackwell Verlag GmbH

**Correspondence**

Professor Markus Ruhnke, Klinik für Innere Medizin, Hämatologie/Onkologie und Palliativmedizin, Evangelisches Klinikum Bethel, Johannesstift, Schildescher Straße 99, 33611 Bielefeld, Germany.  
Email: markruhnke@online.de

**Summary**

**Background:** Invasive fungal diseases remain a major cause of morbidity and mortality in cancer patients undergoing intensive cytotoxic therapy. The choice of the most appropriate antifungal treatment (AFT) depends on the fungal species suspected or identified, the patient's risk factors (eg length and depth of granulocytopenia) and the expected side effects.

**Objectives:** Since the last edition of recommendations for 'Treatment of invasive fungal infections in cancer patients' of the Infectious Diseases Working Party (AGIHO) of the German Society of Hematology and Medical Oncology (DGHO) in 2013, treatment strategies were gradually moving away from solely empirical therapy of presumed or possible invasive fungal diseases (IFDs) towards pre-emptive therapy of probable IFD.

**Methods:** The guideline was prepared by German clinical experts for infections in cancer patients in a stepwise consensus process. MEDLINE was systematically searched for English-language publications from January 1975 up to September 2019 using the key terms such as 'invasive fungal infection' and/or 'invasive fungal disease' and at least one of the following: antifungal agents, cancer, haematological malignancy, antifungal therapy, neutropenia, granulocytopenia, mycoses, aspergillosis, candidosis and mucormycosis.

**Results:** AFT of IFDs in cancer patients may include not only antifungal agents but also non-pharmacologic treatment. In addition, the armamentarium of antifungals for treatment of IFDs has been broadened (eg licensing of isavuconazole). Additional antifungals are currently under investigation or in clinical trials.

**Conclusions:** Here, updated recommendations for the treatment of proven or probable IFDs are given. All recommendations including the levels of evidence are summarised in tables to give the reader rapid access to key information.

**KEYWORDS**

antifungal agents, aspergillosis, candidosis- mucormycosis, haematologic malignancies-cancer-IFD, invasive fungal disease, mycoses, therapy

**1 | BACKGROUND**

In cancer patients, invasive fungal diseases (IFDs) remain an important complication still causing high mortality and morbidity. Chemotherapy or transplantation procedures are often delayed or postponed in patients with IFD which might lead to poor overall survival, in particular after stem cell transplantation. Adherence to guidelines was found to be suboptimal in the past, but adherence to guidelines may lead to a higher response rate to first-line antifungal treatment (AFT) of invasive aspergillosis in leukaemic patients.<sup>1</sup>

In recent years, recommended treatment strategies were gradually moving away from solely empirical therapy of possible IFD towards pre-emptive therapy of probable IFD. AFT of IFDs in cancer patients may include not only antifungal agents but non-drug treatment as well. Furthermore, new antifungal agents have been

studied in large trials (eg isavuconazole). For these reasons, the Infectious Diseases Working Party (AGIHO) of the German Society of Hematology and Medical Oncology (DGHO) presents its updated recommendations from the 2013 guideline.<sup>2</sup>

**2 | OBJECTIVES**

The current version of the guideline focuses on patients with haematologic malignancies and/or solid tumours and includes treatment of IFDs caused by the species *Aspergillus*, *Candida*, *Cryptococcus*, *Scedosporium*, *Fusarium*, *Mucor* (formerly *Zygomycetes*) and *Trichosporon*. Chronic or superficial fungal infections were excluded. We hereby provide an overview of the treatment options for IFDs and classify the recommendations according to their evidence level.

### 3 | METHODS

The guideline was prepared by German clinical experts for infections in cancer patients in a stepwise consensus process. Systematic computerised literature searches of the English-language literature using PubMed were conducted by MR, GM, NA, JP, OAC, MSH, JS, MLT, DT, JH, OP, MK, DB and SS. Briefly, MEDLINE was systematically searched for English-language publications from January 1975 up to September 2019 using the key term 'invasive fungal infection' and/or 'invasive fungal disease' and at least one of the following: antifungal agents, cancer, haematological malignancy, antifungal therapy, neutropenia, granulocytopenia, mycoses, aspergillosis, candidosis and mucormycosis. Studies published in form of abstracts were only considered if their data lead to a change in the level of recommendation for a given treatment. For the current update, the expert panel completed the review and analysis of data published since 2013. Results were discussed in two telephone conferences with all members of the working group. Secondly, the revision process was performed by repeated circulation of a draft (MR) by electronic mail integrating proposals from all group members. After integration of all proposals, approval was achieved after public discussion in two AGIHO general meetings (March and September 2018) and circulation of the final manuscript in September 2019 as performed for other guidelines of the working group.

The strength of recommendation for or against its use and the grade of evidence were adapted to the criteria of the European Society for Clinical Microbiology and Infectious Diseases (ESCMID)<sup>3-6</sup> used in other AGIHO guidelines.<sup>3,7,8</sup> The synopsis of the strength of recommendation and the grade of evidence is given in Table 1. Where the recommendations did not change since 2013, the reader may refer to that previous publication.<sup>2</sup> The status of licence for the presented medications was not considered, and substances are solely recommended based on available clinical study data. Therefore, the responsibility for a selected therapy is exclusively that of the ordering physician. Currently used dosages of available fungal agents are listed in Table 2.

### 4 | RESULTS

#### 4.1 | Empirical vs pre-emptive antifungal therapy

The time point of initiation of antifungal therapy (AFT) in granulocytopenic high-risk patients with fever and prolonged granulocytopenia is critical. Current guidelines<sup>9</sup> recommend starting empirical systemic mold-active AFT in this patient cohort in case of persistent fever of unknown origin (FUO) after 4-6 days of broad-spectrum anti-pseudomonal beta-lactams. In a recent meta-analysis,<sup>10</sup> this empirical antifungal strategy showed a high efficacy, favouring echinocandins as the preferable class of agents. However, it has drawbacks including the risk of side effects, drug-drug interactions, emergence of resistant fungal pathogens and costs, and another meta-analysis supports the use of pre-emptive antifungal therapy

**TABLE 1** Grading of recommendations, adopted from the European Society of Clinical Microbiology and Infectious Diseases (ESCMID)<sup>3-6</sup>

Category, grade	Definition
<b>Strength of recommendation</b>	
A	AGIHO strongly supports a recommendation for use
B	AGIHO moderately supports a recommendation for use
C	AGIHO marginally supports a recommendation for use
D	AGIHO supports a recommendation against use
<b>Quality of evidence</b>	
I	Evidence from at least 1 properly designed randomized, controlled trial
II and respective indices	Evidence from at least 1 well-designed clinical trial, without randomization; from cohort or case-controlled analytic studies (preferably from >1 centre); from multiple time series; or from dramatic results of uncontrolled experiments
II <sub>r</sub>	Meta-analysis or systematic review of RCT
II <sub>t</sub>	Transferred evidence, ie results from different patient cohorts or similar immune status situation
II <sub>h</sub>	Comparator group historical control
II <sub>u</sub>	Uncontrolled trials
II <sub>a</sub>	Published abstract (presented at an international symposium or meeting)
III	Evidence from opinions of respected authorities, based on clinical experience, descriptive case studies

by showing non-inferiority and substantial resource reduction in comparison with the empirical approach.<sup>11</sup> In parallel, diagnostic efforts to identify a source of infection, for example, pulmonary infiltrates suggestive of invasive mold infection<sup>8</sup> and serial testing for fungal biomarkers such as *Aspergillus* galactomannan alone or in combination with molecular targets by using PCR assays<sup>12-15</sup> have been strongly advocated in addition to repeated blood cultures and physical examinations.<sup>9</sup> For AFT implementation, this pre-emptive or 'diagnostic-driven' therapy (ie the diagnostic work-up shows suspicious findings before initiation of antifungal treatment) has been compared with empirical ('fever-driven') AFT.<sup>14,16-19</sup> While overall and infection-related mortality did not show statistically significant differences, the rate of proven or probable invasive fungal disease has been substantially higher in patients not treated empirically. As a result, the routine use of the diagnostic-driven approach cannot be recommended as long as the current diagnostic tools lack sensitivity and/or specificity and thresholds triggering AFT are not clearly defined (BII). Furthermore, treatment delay might enhance mortality in this patient population. Efforts to further reduce the risk of IFD by

starting empirical mold-active AFT on day 1 of fever during granulocytopenia in high-risk patients have failed.<sup>20</sup>

Empirical and pre-emptive antifungal treatment is not mutually exclusive.<sup>21-23</sup> In granulocytopenic high-risk patients with FUO, empirical mold-active AFT should be started after 4 days of full-dose antipseudomonal beta-lactam treatment (AII). In patients receiving systemic mold-active antifungal prophylaxis with posaconazole or voriconazole, a switch to caspofungin or liposomal amphotericin B is a standard of care (BII), but data on breakthrough fungal infections do not clearly back-up this approach.<sup>24</sup> As an alternative, in patients with adequate blood levels of the azole, this systemic prophylaxis can be continued, while fungal biomarkers (GM  $\pm$  PCR) should be checked for signals of breakthrough mold infection and blood cultures and abdominal ultrasound done for breakthrough yeast infection (BIII). In order to get away from empirical AFT, stringent follow-up of clinical signs and symptoms, microbiological and radiological diagnostics must be further pursued, for example daily clinical examination, repeat thoracic CT scan, follow-up of biomarkers such as CRP, and other procedures such as repeat abdominal ultrasound in case of elevated liver function tests (BIII). In patients with lung infiltrates or sinusitis, particularly those evolving despite broad-spectrum antibacterial therapy, prompt pre-emptive AFT directed against *Aspergillus* spp. and Mucorales must be considered, while newly emerging hepatic lesions should give reason for AFT active against a broad spectrum of *Candida* spp. (BIII). See algorithm in Figure 1.

## 4.2 | Treatment of invasive aspergillosis

Acute invasive pulmonary aspergillosis (IPA) is the most frequent manifestation of systemic/invasive aspergillosis (IA) in granulocytopenic patients<sup>25</sup> with a fatality rate that ranges from 30% to 60%.<sup>26-28</sup> Early treatment at first signs of infection is mandatory and improves the chance of survival (AIII).<sup>29</sup> See Table 3a,b.

**Granulocytopenic patients:** Although data are limited, the response to liposomal amphotericin B is reduced by >20% in the granulocytopenic host (43%) as compared to non-granulocytopenic patients (67%) with invasive aspergillosis in contrast to voriconazole where response rates were similar in patients with and without granulocytopenia (50.8% vs 54.3%, respectively).<sup>30,31</sup> In a phase 3, double-blind, randomised trial between isavuconazole and voriconazole, response rates in granulocytopenic patients were reported to be similar.<sup>32,33</sup>

### 4.2.1 | Antifungal therapy

#### *Azoles*

**Isavuconazole:** In a phase 3, double-blind, global multicentre, comparative study, isavuconazole was compared to voriconazole in patients with suspected invasive mold disease.<sup>32</sup> Primary efficacy endpoint was all-cause mortality from first dose of study drug to day

42. Adult patients (n = 527) were randomly assigned (258 received study medication per group). At baseline, 65 (13%) patients had proven invasive mold disease and 207 (40%) had probable invasive mold disease. *Aspergillus* spp. were identified in 30%-34% as a causative pathogen. In 50%-53% of cases, *Aspergillus* galactomannan was the only mycological proof for IFD. Proven IFD was diagnosed in 11% (isavuconazole) vs 14% (voriconazole) of cases, respectively. All-cause mortality from first dose of study drug to day 42 for the ITT population was 19% with isavuconazole (48 patients) and 20% with voriconazole. Overall response rate was similar for both drugs (35% for isavuconazole vs 36% for voriconazole) in the mITT population at the end of treatment (EOT). Drug-related adverse events were reported in 109 (42%) patients receiving isavuconazole and 155 (60%) receiving voriconazole ( $P < .001$ ). According to the results of this large study, isavuconazole was non-inferior to voriconazole for the primary treatment of suspected invasive mold disease. In a post hoc analysis, overall and clinical success at EOT was significantly higher for possible IFD compared with proven/probable IFD.<sup>34</sup> This trial offers strong evidence that isavuconazole is an appropriate alternative to voriconazole for first-line treatment of invasive aspergillosis and other mold disease (AI). In addition, in patients who do not tolerate posaconazole due to toxicity, isavuconazole was found to be a safe alternative.<sup>35</sup>

**Itraconazole:** Itraconazole has been widely used in patients with haemato-oncological malignancies for prophylaxis, empirical therapy and therapy for proven/probable IA primarily as an oral formulation in the past.<sup>36-39</sup> Large prospective comparative studies in therapy of IA are lacking, and an intravenous formulation was studied only in a small cohort of haematological patients.<sup>37</sup> In addition, a highly variable bioavailability and high potential for drug-drug interactions limit its use. Since voriconazole and most recently isavuconazole have been established for first-line therapy of IA as a result from large comparative studies, itraconazole does not play a major role in patients with haemato-oncological malignancies in industrialised countries any more. Itraconazole may serve as an alternative if voriconazole or isavuconazole are not available for first-line therapy of IA or posaconazole is not available for 2nd therapy of IA (CIII).

**Posaconazole:** Posaconazole was licensed for second-line therapy of aspergillosis but was never studied in first-line therapy of IA. In a retrospective comparison of posaconazole vs standard treatment (eg AmB lipid formulations and itraconazole) in a historical control group, patients (including granulocytopenic patients) demonstrated a response rate of 42% vs 26%, respectively.<sup>40</sup> The response to posaconazole correlated with plasma concentrations. Pharmacokinetics of posaconazole was studied for oral as well as for iv formulations in haematological patients and other patient groups.<sup>41-44</sup> Additionally, in a retrospective not stratified investigation the response rate of posaconazole compared favourably to high-dose AmB lipid formulations ( $\geq 7.5$  mg/kg) or caspofungin plus high-dose lipid-AmB in salvage therapy for invasive aspergillosis. Response rates were 40% vs 8% vs 11%, respectively, in 143 patients with haematological malignancies.<sup>45</sup> Thus, posaconazole is recommended as salvage therapy in this patient group (BII). Posaconazole is generally well tolerated,

**TABLE 2** Currently used dosages of available antifungal agents

Antifungal drug	Daily dosage	Loading dose	Remarks
<b>Polyenes</b>			
Amphotericin B Deoxycholate (D-AMB) <sup>a</sup>	0.7-1.0 mg/kg/d iv	–	Not regarded as 1st-line therapy in IA
Liposomal Amphotericin B (L-AMB)	3 (-10) mg/kg/d iv Optional in body weight > 100 kg 300 or 500 mg iv/d instead of 3 or 5 mg/kg/d iv	–	10 mg/kg/d is associated with higher nephrotoxicity Optional fixed dose in >100 kg
Amphotericin Lipid Complex (ABLC) <sup>b</sup>	5 mg/kg/d iv	–	Not regarded as 1st-line therapy in IA
Amphotericin Colloidal Dispersion (ABCD) <sup>c</sup>	3-4 mg/kg/d iv	–	Not regarded as 1st-line therapy in IA
<b>Echinocandins</b>			
Anidulafungin	From day 2, 100 mg/d iv	Day 1, loading 200 mg/d	Not data for monotherapy in aspergillosis 1st line for candidosis
Caspofungin <sup>d</sup>	From day 2 weight <80 kg 50 mg/d Weight >80 kg: 70 mg Optional up to 150 mg/d	Day 1, loading 70 mg/d	1st line for candidosis 2nd line for aspergillosis
Micafungin	1 × 100 mg/d iv Optional dose increase up to 1 × 200 mg/d iv	No loading	1st line for candidosis 2nd line for aspergillosis
<b>Azoles</b>			
Fluconazole	400-800 mg/d (oral or iv)	Loading on day 1 double dose (800 or 1600 mg) iv	Not effective in mould disease 2nd line in candidosis or echinocandins not feasible cryptococcosis (combination)
Isavuconazole	From day 3, 1 × 200 mg/d iv or oral	Day 1 + 2, loading 3 × 200 mg iv or oral;	1st line for aspergillosis efficacy in mucormycoses
Itraconazole <sup>e</sup>	From day 3, 1 × 200 mg iv (or oral, capsule/ oral suspension)	Day 1 + 2, loading 2 × 200 mg iv (or oral capsule/ oral suspension)	Alternative in aspergillosis if isavuconazole/ voriconazole not available
Posaconazole <sup>f</sup>	From day 2, 1 × 300 mg iv or oral For oral suspension: 4 × 200 mg/d or 2 × 400 mg (with food)	Day 1, loading 2 × 300 mg iv or oral tablet 2 × 300 mg/d for oral suspension: day 1, 4 × 200 mg/d (with food)	2nd line for aspergillosis and salvage 2nd line mucormycosis
Voriconazole <sup>g,h</sup>	From day 2, 2 × 4 mg/kg/d iv or orally from day 2, 2 × 2-300 mg/d (adults >40 kg)	Day 1, loading 2 × 6 mg/kg/d iv or orally day 1, 2 × 400 mg/d	1st line for aspergillosis 2nd line in candidosis or echinocandins not feasible
<b>Combination therapy</b>			
Liposomal Amphotericin B + Fluconazole	3 mg/kg/d iv 800 mg/d iv		Invasive candidosis/ candidemia 2nd-line CNS cryptococcosis
Liposomal Amphotericin B + Flucytosine	3-5 mg/kg/d iv 4 × 25 mg/kg/d iv		CNS cryptococcosis; CNS/endocarditis candidosis
Voriconazole + Anidulafungin	From day 2, 2 × 4 mg/kg/d iv From day 2, 100 mg/d iv	Day 1, loading 2 × 6 mg/kg/d iv Day 1, loading 200 mg/d iv	Invasive aspergillosis (high-risk 1st line)

<sup>a</sup>Use of Amphotericin B desoxycholate alone or in combination is discouraged in the current ESCMID guideline because of AmB-D toxicity. Alternatively, liposomal amphotericin B should be used.

<sup>b</sup>Amphotericin Lipid Complex (ABLC) availability in Europe is restricted to few countries.

<sup>c</sup>ABCD is not licenced in many countries.

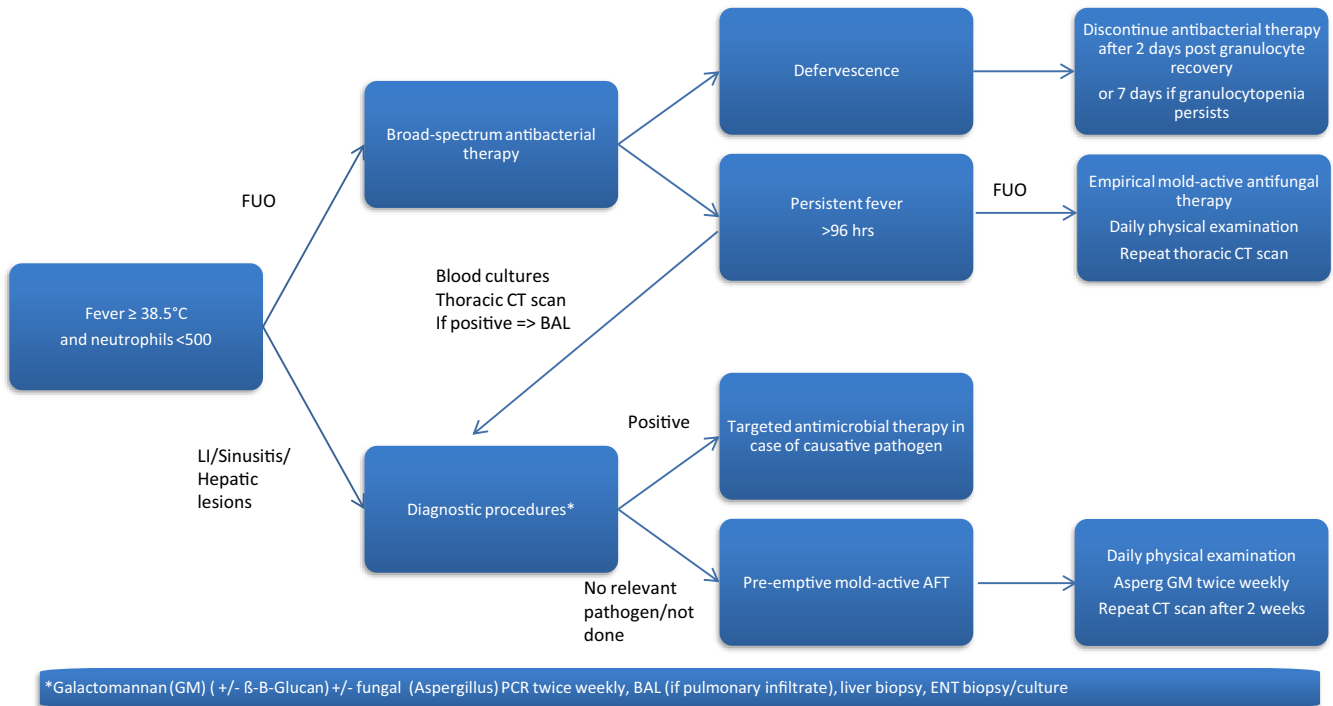
<sup>d</sup>Dose modification in patients with more than 80 kg and with liver failure.

<sup>e</sup>Dose of itraconazole may differ according to the licenced indication and/or formulation. Major interindividual variation of serum levels/ pk parameter observed.

<sup>f</sup>Dosage of posaconazole may differ according licenced indication and/or formulation (eg oral suspension).

<sup>g</sup>Adult patients weighting <40 kg: oral maintenance dose 100 or 150 mg every 12 h (See PRESCRIBING INFORMATION).

<sup>h</sup>Evidence according to ESCMID European Fungal Infection Study Group (EFISG) criteria.



**FIGURE 1** Empirical and pre-emptive AFT in patients with granulocytopenia (<500 cells/μL) and high risk for IFD

also in long-term use.<sup>46</sup> The drug is a substrate of both uridinediphosphate glucuronosyltransferase (UGT) and the transporter P-glycoprotein, but is not significantly metabolised by cytochrome P450 although the compound inhibits isoenzyme 3A4.<sup>47</sup> Therefore, various potential interactions have to be considered if co-medications are given. Posaconazole also demonstrates activity in mucormycosis, which is clinically difficult to distinguish from aspergillosis of lungs, paranasal sinuses or CNS.<sup>48</sup> The oral suspension may be safely replaced in the setting of antifungal prophylaxis by the tablet which is given only once daily (300 mg). According to a phase-3 PK study, 300 mg posaconazole (as tablets) once daily was well tolerated and demonstrated a safety profile similar to that reported for posaconazole oral suspension.<sup>49</sup> Posaconazole should be administered with food, when given orally. Alternatively, posaconazole can be given intravenously.<sup>41,49</sup> The co-medication with a proton-pump inhibitor might limit the posaconazole exposure.<sup>50,51</sup>

**Voriconazole:** The randomised comparison between voriconazole and amphotericin B deoxycholate (D-AmB; both followed by other licensed antifungal agents in the case of failure/intolerance) included patients with a malignant underlying disease or another immunocompromising condition. In this study voriconazole had a significantly higher response and survival rate including fewer *Aspergillus*-related deaths and side effects compared to D-AmB.<sup>31</sup> Since then, voriconazole has been established as the standard for treatment of invasive aspergillosis as recommended in other guidelines.<sup>5,52,53</sup> According to this study results, the AGIHO recommends voriconazole as first-line therapy for aspergillosis (AI). In case of a different first-line therapy, voriconazole is recommended for salvage treatment of invasive aspergillosis (BII). In addition,

voriconazole is more active in vitro not only against *A. fumigatus* but *A. terreus* compared to D-AmB.<sup>54,55</sup> After oral or intravenous administration, adequate concentrations of voriconazole were documented in many body sites including brain parenchyma.<sup>56-58</sup> However, a large variability in trough plasma levels has been observed.<sup>59,60</sup> Studies demonstrated a positive correlation between plasma levels, clinical efficacy and toxicity. Plasma concentrations of >1 mg/L were found to be correlated with response to therapy. However, plasma levels >5.5 mg/L were associated with neurotoxicity.<sup>61</sup> In contrast, in lung transplant recipients a cut-off for toxicity was not identified.<sup>61</sup> Therapeutic concentrations could only be achieved with a dose of 2 × 200 mg oral voriconazole in about 50% of patients, increasing to about 70% with 2 × 300 mg and nearly 100% with 2 × 400 mg given.<sup>62</sup> It is suggested that voriconazole TDM to aim for serum concentrations between 1.0 and 6.0 mg/L during therapy may be warranted to optimise clinical success and minimise toxicity<sup>63</sup> (see also chapter 'therapeutic drug monitoring'). Main side effects (AEs) of voriconazole therapy are usually reversible. However, AEs such as visual disturbances may occur in up to 40% of patients. Voriconazole metabolism involves various hepatic cytochrome P450 isoenzymes, primarily the CYP2C19 and elimination capacity correlated with the CYP2C19 genotype.<sup>64</sup> Poor metabolisers (more frequent in Asian individuals) may exhibit up to fourfold higher voriconazole levels than extensive metabolisers. However, empiric voriconazole therapy was found to be safe in a cohort of febrile granulocytopenic patients in Japan.<sup>65</sup> It is suggested that CYP2C19 polymorphisms may be a cause for voriconazole-refractory IA in Asian people.<sup>66</sup> Primarily due to cytochrome P450 metabolism, voriconazole can interact with a large



**TABLE 3** Recommendations for specific invasive fungal diseases incl. therapeutic drug monitoring. Invasive/systemic aspergillosis—(a) first-line therapy and (b) second-line/salvage therapy

(a) Population	Intention	Intervention	SoR	QoE	Reference
Any	To cure	Voriconazole	A	I	(31,32)
Any	To cure	Isavuconazole	A	I	(32)
Any	To cure	Liposomal amphotericin B	A	II	(30)
Any	To cure	Voriconazole + Anidulafungin combination	B	I	(82)
Any	To cure	Posaconazole	C	III	Weak data
Any	To cure	Caspofungin	C	II	(67,69,72)
Any	To cure	Micafungin	C	II	(78)
Any	To cure	Itraconazole	C	III	(37)
Any	To cure	Anidulafungin	D	III	No data for monotherapy
Any	To cure	Amphotericin B lipid complex (ABLC)	D	I	(200,337)
Any	To cure	Amphotericin B Deoxycholate	D	I	(338)
Any	To cure	Amphotericin B colloidal dispersion (ABCD)	D	I	(83)
(b) Population	Intention	Intervention	SoR	QoE	Reference
Any	To cure	Liposomal Amphotericin B	B	II	(45,339,340)
Any	To cure	Caspofungin	B	II	(75)
Any	To cure	Posaconazole	B	II	(40,45)
Any	To cure	Voriconazole	B	II	(31)
Any	To cure	Micafungin mono- or combination	C	II	(79,341)
Any	To cure	Voriconazole + Caspofungin mono- or combination	C	II	(98)
Any	To cure	Amphotericin B lipid complex	B	III	(200)

number of other drugs. Therefore, contraindications and co-mediations (eg vinca alkaloids, statins, chinidin, proton-pump inhibitors) have to be monitored closely.

#### *Echinocandins*

**Caspofungin:** A small phase II study of caspofungin as first-line therapy demonstrated survival rates of 66% (6 weeks) and 53% (12 weeks) in 61 patients with haematologic malignancies.<sup>67</sup> Response (complete, partial) was observed in 32% of patients (MITT). Most patients were not in remission of their underlying disease, 72% presented with severe granulocytopenia for >10 days, and in contrast to other studies, aspergillosis had to be proven or probable strictly according to (earlier) EORTC-MSG criteria.<sup>68</sup> An EORTC study in allogeneic stem cell transplanted patients was stopped due to inadequate recruitment with 42 patients enrolled. At week 6 and week 12, the survival rate was 79% and 50%, respectively.<sup>69</sup> In a prospective observational registry, 12 out of 20 patients responded to caspofungin first-line treatment.<sup>70</sup> A multicentre, prospective non-comparative study from Spain in 115 patients with haematological malignancies observed a favourable response in 79% (27/34) of patients with IA and 77% (20/26) with invasive candidosis.<sup>71</sup> In a phase II dose escalation study of caspofungin for invasive aspergillosis, dosages up to 200 mg daily were studied.<sup>72</sup> Daily doses of up to 200 mg caspofungin were

well-tolerated, and the maximum tolerated dose was not reached, and the pharmacokinetics was linear. In granulocytopenic patients with invasive candidosis, a higher dose of caspofungin (150 mg/d) led to higher response rates as compared to the standard dose (50 mg/d).<sup>73</sup> It remains unclear whether patients with IA may benefit clinically from a higher daily dose of caspofungin or do have an increased risk for toxicity (eg cardiac toxicity).<sup>74</sup>

When used for salvage treatment, caspofungin resulted in a response rate of 45%–49% in two non-comparative studies of patients with invasive aspergillosis and failure of or intolerance to standard antifungal therapy.<sup>75,76</sup> A case collection of 118 patients demonstrated a response rate of 61%.<sup>77</sup> In the CAN-DO study, 45 from 81 patients responded to caspofungin treatment.<sup>70</sup> Caspofungin is recommended for salvage therapy (BII).

**Micafungin:** Micafungin has been investigated mostly in salvage therapy studies and retrospective analyses as mono- and particularly combination therapy which resulted in efficacy rates of about 25%–36%.<sup>78,79</sup>

**Anidulafungin:** Anidulafungin as monotherapy for treatment of IA has not been studied properly to allow inclusion of this drug into the therapy algorithms as first-line (or even salvage) therapy of IA.<sup>80,81</sup> In combination with voriconazole, an additive efficacy and reduced mortality rate at six weeks has been observed as compared to voriconazole monotherapy (see chapter combination therapy).<sup>82</sup>

The AGIHO working group considers caspofungin (or micafungin) as a therapeutic option in the first-line therapy (CII), but echinocandins may be used only when isavuconazole/ voriconazole or liposomal amphotericin B are not considered suitable for primary therapy. The role of micafungin in the treatment of acute invasive aspergillosis has not been clarified in cancer patients so far, and anidulafungin has not been studied as monotherapy for primary therapy of IA at all.

#### *Amphotericin B formulations*

**Amphotericin B lipid complex (ABLC):** A retrospective analysis of a large company-based dataset (Collaborative Exchange of Antifungal Research; CLEAR) showed a 44% efficacy in about 400 patients with IA (55% response in 42 granulocytopenic patients),<sup>31</sup> and 31% response rate in patients after allogeneic stem cell transplantation,<sup>74</sup> mainly in patients with second-line therapy (BIII). Therefore, ABLC is not regarded as first choice for first-line therapy of IA (DI).

**Amphotericin B colloidal dispersion (ABCD):** Amphotericin B colloidal dispersion (ABCD; 6 mg/kg/d) was compared with amphotericin B in a randomised, double-blind, multicentre trial for the treatment of invasive aspergillosis in 174 patients.<sup>83</sup> Therapeutic response, mortality and death due to fungal infection were similar with both drugs. Renal toxicity was less frequent with ABCD but infusion-related toxicity was higher. This profile led to the recommendation against the use of ABCD (DI). In addition, the drug is no more available in Europe.

**Liposomal amphotericin B (L-AmB):** There are several liposomal AmB products available, but only one licensed L-AmB (AmBisome®) is available in Europe and North America.<sup>84</sup> Several non-comparative studies with L-AmB for second-line therapy exist from the early 1990s which included only smaller numbers of patients and resulted in response rates of 50%-70%.<sup>85</sup> In a pooled efficacy analysis, L-AmB therapy resulted in a response rate of 47% for the treatment of invasive aspergillosis.<sup>86</sup> In a randomised study, L-AmB was equally efficacious compared to D-AmB in the first-line therapy of invasive mycosis,<sup>87</sup> but the study was not restricted to patients with IA. The efficacy of L-AmB vs ABLC in the first-line therapy has been compared in an analysis of eight open-label studies with more than 1000 patients resulting in a response rate of 61% vs 46% favouring L-AmB over ABLC.<sup>88</sup> A retrospective study in 158 consecutive patients with mainly acute leukaemia or allogeneic stem cell transplantation receiving L-AmB or ABLC for invasive aspergillosis resulted in a poor outcome of both groups (12%).<sup>89</sup> ABLC was associated with significantly higher nephrotoxicity rates compared to L-AmB.<sup>89</sup>

The studied dosages of L-AmB for treatment of invasive aspergillosis are 1-10 mg/kg/d (manufacturer recommendation: 1-5 mg/kg).<sup>30,87,90</sup> A randomised study comparing L-AmB 4 mg/kg vs 1 mg/kg resulted in similar efficacy rates, but survival at day 14 and response in patients with proven aspergillosis was higher in the 4 mg/kg arm.<sup>90</sup> A randomised comparison of L-AmB 3 mg/kg vs 10 mg/kg (mainly cancer patients) in first-line therapy of invasive aspergillosis showed equal efficacy but an increased toxicity with the higher dosage.<sup>30</sup> The response rate was high and comparable to voriconazole.

In a recent pharmacokinetic study with L-AmB in obese individuals (>100 kg), it was calculated that a fixed dose of 300 mg L-AmB may be an alternative instead of 3 mg/kg L-AmB.<sup>91</sup>

The AGIHO recommends L-AmB (3 mg/kg) for the first-line treatment of IA with lesser strength than isavuconazole or voriconazole (AII), since all available trials did not compare L-AmB with a standard treatment. L-AmB may be also used as second-line treatment (BII).<sup>92</sup>

**Amphotericin B deoxycholate (D-AmB):** Intravenous therapy with D-AmB had been the therapeutic gold standard for IA with response rates of 30 (-50)% for many years in the past.<sup>93</sup> Maximum tolerable daily dosages of up to 1.5 mg/kg have been recommended. Comparative clinical studies on dose regimens are, however, not available. Due to its high toxicity and inferiority compared to voriconazole in a randomised controlled study,<sup>31</sup> we strongly discourage the use D-AmB (DI).

#### *Combination therapy*

The benefit of combination of D-AmB plus 5-flucytosine has not been substantiated by appropriate clinical trials.<sup>94,95</sup> There are limited data from uncontrolled trials with response rates of 42% for combinations of L-AmB and caspofungin as primary or salvage therapy,<sup>96</sup> 55% for combinations of caspofungin and polyenes or triazoles in cancer patients,<sup>97</sup> and a significantly reduced mortality rate for patients receiving caspofungin plus voriconazole vs voriconazole alone in refractory aspergillosis in a historically controlled trial among stem cell transplant recipients.<sup>98</sup> A randomised pilot study comparing the combination of L-AmB plus caspofungin (standard dosages) to high-dose L-AmB in patients with haematological malignancies resulted in a better response with the combination at the end of treatment, but similar overall survival after 12 weeks and the number of patients included (n = 30) was rather small.<sup>99</sup> A large prospective randomised trial comparing voriconazole monotherapy to voriconazole plus anidulafungin for first-line therapy did show a not significant trend towards superiority of the combination for the primary endpoint of overall survival at week six for the whole study cohort. Mortality rates at 6 weeks were 19.3% (26 of 135) for combination therapy and 27.5% (39 of 142) for monotherapy.<sup>82</sup> However, compared with voriconazole monotherapy, combination therapy of voriconazole with anidulafungin led to higher survival in specific subgroups of patients with IA, but limitations in power of the study preclude definitive conclusions about superiority. In summary, the combination therapy of voriconazole plus anidulafungin may be considered as an alternative in severely ill haematological patients (BI).

#### *Salvage therapy*

Response to antifungal therapy in patients with invasive mold disease may be defined either as success (complete or partial) or failure (stable, progression or death).<sup>100</sup> It is not clear, whether and when patient with a stable response (minor or no improvement of signs and symptoms or persistent isolation of moulds) should receive a salvage therapy. However, when progression of disease



is evident (with worsening of signs and symptoms plus new sites of disease or radiological worsening) salvage therapy is indicated. In general, radiological improvement may be not observed unless a minimum of 7-14 days of full-dose treatment is given. It was observed that despite administration of effective antifungal treatment, the median volume of lesions increased fourfold during the first week before these lesions stabilised or improved during the second week.<sup>101</sup> Therefore, in a clinical stable situation a reliable clinical response may not be assessed before 10-14 days of adequate therapy (BIII).

Apart from evident failure due to intrinsic resistance of the pathogen (eg *A terreus* to AmB), lack of adequate drug levels (see chapter therapeutic drug monitoring), intolerance or severe organ toxicity, non-response of IA to an established antifungal therapy should be stated with caution.<sup>100,102</sup> Since most available studies for salvage therapy included patients who failed to respond to D-AmB as a first-line treatment, no definite conclusion can be drawn to salvage treatment after failure of newer antifungal agents (eg triazoles and echinocandins). In general, a switch of the antifungal class is recommended (CIII).

**Invasive aspergillosis occurring during posaconazole or voriconazole prophylaxis:** Recommendations for the treatment of invasive mycoses have to consider the prophylactic regimens, but so far meaningful studies in this field are lacking. However, breakthrough IFDs have been repeatedly reported under prophylaxis and/ or treatment with either voriconazole or posaconazole.<sup>24,103-109</sup> These breakthrough IFDs may either due to resistant fungal pathogens (eg *Mucor* spp.) and/ or low through serum concentration of the triazole.<sup>103,110</sup> A definition for breakthrough IFD has been recently proposed by the Mycoses Study Group Education and Research Consortium (MSG) and the European Confederation of Medical Mycology (ECMM).<sup>111</sup> Therefore, the AGIHO recommends the switch to another class of antifungal agent (CIII).

**Recommendation:** For primary therapy of IA, isavuconazole and voriconazole are equally effective, with less adverse effects for isavuconazole (AI). Liposomal amphotericin B is an effective alternative (AII). Combination therapy with voriconazole plus anidulafungin is appropriate in selected patients (BI). Echinocandins are not regarded appropriate for first-line therapy of IA (CII). The use of D-AmB, ABCD and ABLC must be discouraged (DI). For salvage therapy L-AmB, caspofungin, posaconazole and voriconazole are regarded as equally effective (BII), but switch to another class of AFT as in primary therapy is recommended (CIII).

#### Duration of antifungal treatment

Generally, the antifungal therapy should be continued during the period of granulocytopenia and until the manifestations of IA have been completely resolved or are reduced to residual scarring, which may last up to 12 weeks (BIII). In clinical trials of primary antifungal therapy in IA, the minimum period of observation was at least 6 weeks for assessment of response (eg resolution of signs and symptoms, resolution of radiological lesions, documented mycological clearance of infected sites).<sup>100</sup>

## 4.2.2 | Other manifestations

**Invasive sinus aspergillosis:** *Aspergillus* sinusitis was described in individuals with acute leukaemia or after allogeneic stem cell transplantation.<sup>112</sup> The IFD is primarily caused by *A flavus* or *A fumigatus*.<sup>113</sup> Frequently, additional surgical debridement is required (BII) (see chapter interventional strategies). Overall, *Aspergillus* sinusitis has been associated with a mortality rate ranging from 26% to 66% while treated with conventional AmB.<sup>114</sup> Therapy recommendations do not differ from pulmonary manifestations (see Table 2).

**Aspergillosis of the CNS:** *Aspergillus* spp. rarely cause meningitis or micro-abscesses of the brain, but macro-abscesses—especially in severely immunocompromised patients—are most often caused by *A fumigatus* (followed by other moulds such as *Mucor* spp.). In the majority of patients with cerebral IA, the CNS is invaded by haematogenous spread from primary sites of infection such as the lungs. Acute leukaemia is the most common underlying disease.<sup>115</sup> Patients with aspergillosis within the CNS typically present with focal neurological signs such as pareses or seizures. Overall mortality is still high reaching 69% (with IFD-attributable mortality 33%) in a recent study from Italy.<sup>115</sup> Comparable studies regarding drug treatment of CNS aspergillosis do not exist, but D-AmB was found to be not effective.<sup>116</sup> Due to its good penetration into the cerebrospinal fluid and brain tissue, voriconazole is recommended for primary treatment and has shown a survival rate of 30%-40%<sup>117,118</sup> (AII). In a recently published, retrospective study, evaluating 36 patients with IFDs involving the CNS, isavuconazole therapy was associated with a promising 69% survival rate at day 84. A variety of fungal infections were included into this study. However, 18 (64%) of 28 patients with mold infections, including *Mucor*, were reported to be alive at day 84.<sup>119</sup> These data suggest that isavuconazole is similar effective to voriconazole but is active against *Mucor* spp. as well (AII).

Alternatively, L-AmB might be administered in case of contraindication, intolerance or poor response to voriconazole (BIII). According to data from animal studies, significantly enhanced activity was found with the combination therapy of L-AmB plus voriconazole.<sup>120</sup> The role of echinocandins has not been fully explored other than in case reports.<sup>121</sup> A retrospective study of 81 patients with CNS aspergillosis resulted in significantly better survival in patients undergoing surgery.<sup>117</sup> Therefore, surgical resection of singular lesions is recommended together with systemic AFT (AII).

## 4.3 | Treatment of invasive candidosis

In the past, the most common cause of IFD in cancer patients was yeast pathogens, in particular *Candida albicans*, followed by non-*albicans Candida* (NAC) species (eg *Candida glabrata*, *Candida krusei*, *Candida parapsilosis*, *Candida tropicalis*, *Candida kefyr*).<sup>122</sup> The most recent epidemiological study from the EORTC in Europe found NAC (54%) more often than *C albicans* as causative fungal pathogen in

cancer patients (solid tumours and haematological malignancies) with fungemia.<sup>123</sup> However, a recent epidemiological study on candidemia in cancer patients from Italy (SEIFEM 2015-B report) found a significant decrease in the overall incidence during the study period (2011-2015) as compared to an earlier period (1999-2003).<sup>124</sup> Distribution of *Candida* pathogens differ markedly between patients with solid tumours and patients with haematological malignancies.<sup>123</sup> In patients with haematological malignancies, primarily NAC species (in particular *C tropicalis*, *C krusei*) have been identified in 59% of patients with candidemia vs 22% of patients with candidemia due to *C albicans* in Europe, but species such as *C parapsilosis* were reported to be the most prevalent NAC in cancer patients in China.<sup>123,125</sup> The proper identification of the infecting *Candida* spp. is crucial for the choice of antifungal therapy (eg fluconazole-resistant *Candida* spp.).<sup>6</sup> Due to frequent colonisation with *Candida* spp. in hospitalised patients, detection of yeasts in non-sterile material is not sufficient to confirm invasive *Candida* infection. In patients with acute leukaemia, the degree of mucosal damage and degree of granulocytopenia are the most important risk factors for invasive *Candida* infection in contrast to other patient groups at risk for IFD with other 'classical' risk factors (eg central venous catheters).<sup>6</sup> The high pathogen-related mortality, which may approach 50%, should prompt immediate initiation of therapy in all patients with suspected yeasts in the blood culture, as delays in treatment result in an increased mortality.<sup>126</sup> See Table 4a,b.

**Granulocytopenic patients:** Although data are limited, the response rate as shown for therapy with echinocandins or amphotericin B formulations is reduced by approximately 15%-20% in granulocytopenic host as compared to other (non-granulocytopenic) patients with candidemia.<sup>127,128</sup> Prospective trials in granulocytopenic patients will be probably never performed due to small numbers of patients. Therefore, recommendations are adapted to those in non-granulocytopenic cancer patients. The role of catheter removal in granulocytopenic patients is particularly controversial as the gastrointestinal mucosa, damaged by cytotoxic chemotherapy, is thought to be the main port of entry for yeasts into the bloodstream.<sup>129</sup> However, as the central venous line might be colonised, its removal is recommended in these patients as well as in non-granulocytopenic patients by the AGIHO (AII).<sup>6</sup>

### 4.3.1 | Antifungal therapy

#### *Azoles*

A randomised clinical trial and a cohort study did not show a significant difference in antifungal efficacy between fluconazole (400 mg daily) and D-AmB (25-50 mg daily or 0.67 mg/kg daily for granulocytopenic patients) in granulocytopenic patients with systemic *Candida* infection.<sup>130,131</sup> There was a trend towards a lower response to antifungal treatment in patients with neutrophil counts  $\geq 1000/\mu\text{L}$  at enrolment treated with fluconazole (58%) as compared to D-AmB (74%). However, in the small subset of patients with neutrophil counts  $< 1000/\mu\text{L}$  fluconazole appeared to be superior to D-AmB (response rate 77% for fluconazole vs 48% for D-AmB) (CIII).

Voriconazole shows better in vitro susceptibility in non-*albicans Candida* spp. than fluconazole, but only data from salvage therapy studies are available.<sup>132</sup> Granulocytopenic patients were not included in a randomised trial comparing voriconazole to the regimen of D-AmB followed by fluconazole in the primary treatment of candidemia.<sup>133</sup> Efficacy may be comparable to fluconazole but the publication does not provide data in non-granulocytopenic cancer patients (CIII). Isavuconazole was compared to caspofungin in a randomised trial in 450 patients, including some patients with granulocytopenia (n = 25 in the isavuconazole arm vs n = 24 in the caspofungin arm). Overall response was lower with isavuconazole, and isavuconazole failed to demonstrate non-inferiority (primary endpoint) compared to caspofungin.<sup>134</sup> Consequently, isavuconazole is not licensed for treatment of invasive *Candida* infections until today. Data on the clinical efficacy of itraconazole and posaconazole in candidemia are lacking.

#### *Amphotericin B formulations*

The major disadvantages of D-AmB are nephrotoxicity, hypokalemia and acute infusion-related side effects. Various publications report nephrotoxicity with D-AmB resulting in inferior survival especially in haematological cancer patients.<sup>92,135,136</sup>

L-AmB was studied in a randomised study with micafungin for first-line treatment of invasive *Candida* infections.<sup>128</sup> Treatment success at the end of therapy (EOT) was similar with both drugs (89.6% for micafungin and 89.5% for L-AmB, respectively). Efficacy was independent of the *Candida* spp. and primary site of infection, as well as granulocytopenia status (granulocytopenic patients: micafungin n = 32, L-AmB n = 25), APACHE II score and central venous catheter removal. Adverse events (eg nephrotoxicity) were numerically lower with micafungin. Amphotericin B colloidal dispersion (eg Amphocil®) and Amphotericin B lipid complex (eg Abelcet®) are not longer available in many countries including Germany. Both AmB formulations did not show superior clinical efficacy or less toxicity as compared to L-AmB, and the use of these AFs is no more recommended (DI).

The AGIHO favours initial broad-spectrum antifungal therapy with liposomal amphotericin B (L-AMB) in all cancer patients (AIII) together with early catheter removal whenever possible (AII). Other AmB formulations incl. c-AmB are no longer recommended (DI).

#### *Echinocandins*

Echinocandins were not prospectively studied in granulocytopenic patients. In a pooled, post hoc analysis of phase 3 trials, the overall success of micafungin was numerically lower in patients with vs without granulocytopenia (63.6% vs 72.9%).<sup>137</sup> Granulocytopenia duration or the subtype of infecting *Candida* spp. did not impact the overall success rate of micafungin. However, breakthrough candidemia (BC) has been observed during administration of micafungin (150 mg/d) in recipients of an allo-HSCT (*C parapsilosis*, *C glabrata*, *C guilliermondii*).<sup>138</sup> Data may be derived from large randomised trials in (mostly) non-granulocytopenic patient cohorts.<sup>127,128,139</sup> The number of granulocytopenic patients in these trials was limited (max. 10%).

**TABLE 4** Recommendations for specific invasive fungal diseases incl. therapeutic drug monitoring. Invasive/systemic candidosis (other)– (a) first-line therapy and (b) second-line/salvage therapy

(a) Population	Intention	Intervention	SoR	QoE	Reference
All cancer pat.	Cure	Early catheter removal	A	II	(151)
Granulocytopenic cancer pat.	Cure	Caspofungin,	A	It	(71,73)
		Micafungin	A	It	(87,128,133,137)
		L-AmB	C	III	
		Fluconazole/ Voriconazole/ c-AmB/ABLC/ABCD	D	I	
All cancer pat. (non-granulocytopenic)	Cure	Echinocandin	A	I	(127,128,131,133,134,139-143,153,342)
		L-AmB	A	I	
		Azole	C	I	
All cancer pat.	Cure, if clinically no choice other than to retain catheter	Echinocandin L-AmB	A A	III III	(128,153)
All cancer pat.	Switch to oral in responding patients/ step-down strategy	Fluconazole/ Voriconazole	B	II	Optional, if a susceptible species has been confirmed, the patient is clinically stable, oral resorption is not compromised and had no prior azole exposure. Fluconazole is not effective against <i>C. glabrata</i> / <i>C. Krusei</i> (133,139,169)
All cancer pat.	Success/cure (chronic diss. Candidosis)	Fluconazole (≥3 mo)	B	III	(163,343)
		Other azoles effective (Vori?)	C	III	No data
		Lipid AmB (8 wk)	B	III	(128,344)
All cancer pat.	Success/cure	Echinocandin	B	III	(141)
		Combination antifungal therapy	C	III	weak data
		Steroid therapy	C	III	(168)
All cancer pat.	Defervescence	Combination antifungal therapy	C	III	weak data
		Steroid therapy	C	III	(168)
		Isavuconazole	C	III	
		c-AmB/ABLC/ABCD	D	III	
(b) Population	Intention	Intervention	SoR	QoE	Reference
All cancer pat.	Cure	Echinocandin	C	III	No conclusive data
		L-AmB	C	III	
		Azole (Fluconazole/ Voriconazole/	C	III	
		Isavuconazole c-AmB/ABLC/ABCD	D	III	

The study comparing fluconazole (800 mg on day 1 and then 400 mg daily) vs anidulafungin (200 mg on day 1 and then 100 mg daily) demonstrated superiority of anidulafungin (response rate 75% vs 60%) in the treatment of candidemia and invasive *Candida* infections.<sup>139</sup> Anidulafungin fulfilled the criteria for non-inferiority in non-granulocytopenic patients. A direct comparison of caspofungin and micafungin showed similar efficacy and safety. In addition, no difference in safety or efficacy was seen in patients treated with two different dosages of micafungin (100 mg/d or 150 mg/d).<sup>140</sup> Higher dosages of caspofungin (150 mg/d vs 70/50 mg/d) and micafungin (150 mg/d vs 100 mg/d) showed a trend towards improved efficacy in subgroups of patients (APACHE-II score >20, granulocytopenia) and might be used in selected patients.<sup>73,141,142</sup> According to a post hoc analysis, clinical efficacy of micafungin, caspofungin and liposomal

amphotericin B in patients with invasive candidosis and candidemia was similar.<sup>142</sup>

The AGIHO favours initial broad-spectrum antifungal therapy with an echinocandin in all cancer patients (AI) together with early catheter removal whenever feasible (AII).

A switch to (oral) fluconazole (800 mg/d as loading dose, followed by 400 mg/d) or voriconazole (6 mg/kg bid as loading dose, followed by 4 mg/kg bid) is optional, if a susceptible species has been confirmed, the patient is clinically stable, oral resorption is not compromised and had no prior azole exposure (BII).

#### Combination therapy

In non-granulocytopenic patients, the combination of fluconazole (800 mg/d) plus placebo vs fluconazole plus D-AmB (0.7 mg/

kg/d, with the placebo/D-AmB component given only for the first 5-6 days) did not show antagonism, a similar mortality but improved clinical outcome (69% for Flu/D-AmB vs 56% for Flu/Placebo) and more rapid eradication of yeasts from bloodstream compared to fluconazole alone.<sup>143</sup> The combination therapy with D-AmB plus flucytosine has been advocated in earlier times in particular for children with acute myeloid leukaemia and IFDs,<sup>144</sup> but was never studied properly in a subsequent trial.<sup>145,146</sup> In addition, the use of flucytosine needs regular monitoring of plasma levels to avoid toxicity (eg haematotoxicity).<sup>56,147</sup>

In summary, in adult patients with cancer or haematological malignancies there are only limited data which support a recommendation of combination therapies for invasive *Candida* infections (CIII).

#### Salvage therapy

Data on second-line therapy in cancer patients, in particular during granulocytopenia, are limited to case reports, and specific recommendations cannot be given.

**Recommendation:** In summary, The AGIHO favours initial broad-spectrum antifungal therapy with an echinocandin (eg anidulafungin, caspofungin or micafungin) or L-AmB in all cancer patients (AI). Data in granulocytopenic patients are limited. In addition, an early catheter removal is recommended whenever possible (AII). In non-granulocytopenic patients with no prior azole exposure, fluconazole or voriconazole is alternative for the treatment of yeasts in the blood culture while awaiting susceptibility tests (CIII), but according to one trial (anidulafungin vs fluconazole), the echinocandin is regarded as the better option. Combination and/ or salvage therapy are poorly investigated and may be adapted to results of in vitro susceptibility testing (CIII).

#### Duration of antifungal therapy

Duration of treatment in non-granulocytopenic patients is recommended for at least 14 days after the first negative blood culture and resolution of signs and symptoms of candidemia (BI),<sup>6,148</sup> but should be adapted in case of organ manifestations. In individuals who remain granulocytopenic but do have negative blood cultures should be evaluated for resolution of all signs and symptoms of IC before antifungal therapy is stopped (CIII).<sup>6</sup>

### 4.3.2 | Acute disseminated candidosis

Acute disseminated candidosis is the most severe form of systemic *Candida* infection in granulocytopenic patients. It is characterised by haemodynamic instability, persistent positive blood cultures and deep organ and/or skin involvement. Patients present with sepsis, spiking fever, shaking chills and disseminated lesions of the skin and occasionally other organ infections such as endophthalmitis or osteomyelitis.<sup>149</sup> This entity was mostly reported before the use of azole prophylaxis in leukaemia patients and HSCT and appears rare today.<sup>150</sup> Echinocandins and L-AmB may be recommended as initial antifungal treatment (AIt).

In all cancer patients, fundoscopy and abdominal ultrasound (liver, spleen, kidneys) should be performed (during and after recovery from granulocytopenia) to exclude chronic disseminated infection/ hepato-splenic candidosis that may not be associated with clinical symptoms other than fever (BIII).

### 4.3.3 | Management of intravenous lines

Intravenous lines should be removed in cancer patients at initiation of antifungal therapy whenever feasible to reduce IFD-related mortality<sup>151</sup> (AII). If the central venous lines are retained, the duration of candidemia likely increases (from 3 to 6 days) as does the mortality of patients.<sup>152,153</sup> The role of central venous catheter removal in granulocytopenic patients is controversial as the gastrointestinal mucosa, damaged by cytotoxic chemotherapy, is thought to be the main port of entry for yeasts.<sup>154-158</sup> However, as the central venous line might be colonised, its removal is recommended also in granulocytopenic patients (AII). If the catheter is retained, patients should be treated with an echinocandin or L-AmB (AIII) as these agents exhibit a better minimal inhibitory concentration in biofilms.<sup>159</sup>

### 4.3.4 | Chronic disseminated candidosis

If fever persists after neutrophil recovery, chronic disseminated candidosis (CDC; hepatosplenic candidosis) may be considered in haematological patients, even in patients without prior candidemia.<sup>160</sup> CDC is usually no acute life-threatening condition but may require systemic antifungal therapy for months. After stabilisation of signs and symptoms, CDC is not a contraindication for the continuation of chemotherapy or haematopoietic stem cell transplantation or patients even stay in remission with the leukaemia after antifungal therapy.<sup>161-163</sup>

Data on antifungal treatment in patients with CDC are limited to case series with D-AmB given as a single therapy or in combination with flucytosine,<sup>161</sup> lipid formulations of amphotericin B,<sup>164</sup> fluconazole<sup>165</sup> or caspofungin.<sup>166</sup> Due to the need for prolonged antifungal therapy, oral agents such as fluconazole (400-800 mg/d) are recommended if the *Candida* strain was isolated and proven to be susceptible (BIII). Echinocandins or L-AmB should be used as initial therapy in unstable or refractory patients (BIII). Voriconazole or isavuconazole may be alternative options due to a favourable in vitro susceptibility profile but clinical data are lacking (CIII). The duration of antifungal therapy in patients with CDC should be individualised and may be continued until the resolution of all radiographic signs or calcification of the lesions. In recent years, hepatosplenic candidosis is discussed as to represent an immune reconstitution syndrome (IRIS). Steroids may be used in addition to antifungal treatment because these can lead to a rapid resolution of clinical signs and symptoms<sup>167,168</sup> (CIII). In stable patients, intravenous therapy may be switched to oral medication (step down strategy; eg  $\geq 5$  days iv AFT) (BIIIt). This strategy has not been studied in CDC so far, but

is regarded as safe and effective in patients with candidemia (see above).<sup>169</sup>

### 4.3.5 | Other manifestations

**CNS:** CNS infections caused by *Candida* spp. are extremely rare in adult patients with haematological malignancies.<sup>115,170</sup> Classically, patient groups at risk are (a) very low birth weight infants and (b) patients following neurosurgical interventions.<sup>171</sup> Recently, a genetic defect (CARD9 deficiency) has been shown to contribute to *Candida* CNS infections.<sup>172</sup> That genetic defect allows an immunological treatment other than with AFT (eg  $\gamma$ -interferon). Due to lack of data, no clear treatment recommendation can be given. The optimal AFT is likely a combination of L-AmB combined with either flucytosine or fluconazole (CIII).<sup>4</sup> Whether echinocandins (eg caspofungin or high dose micafungin) may be useful to treat *Candida* infections of the CNS is not fully explored.<sup>173-175</sup> It need to be considered the poor CNS penetration of these agents—at least if the blood-brain barrier is intact.<sup>58,175</sup> In case of a brain abscess, additional drainage or surgical resection is recommended (BIIt).

**Urinary tract:** In a majority of episodes in adult patients in critical care facilities, candiduria represents colonisation, and antifungal therapy is not required.<sup>176</sup> For urinary tract *Candida* infection, fluconazole has been proven to be effective in mainly non-granulocytopenic patients and is the drug of choice, if a susceptible *Candida* spp. is cultured (AI).<sup>177</sup> The optimal AFT for candiduria in granulocytopenic patients is unclear, but candiduria may be caused by (not-detected) candidemia or acute disseminated candidosis and may require systemic AFT.<sup>178</sup> If a urine catheter is in place, it should be removed (BIIt).<sup>148,176</sup>

## 4.4 | Treatment of mucormycosis

Mucormycosis is an emerging invasive fungal infection in patients with haematological malignancies and allogeneic stem cell transplantation.<sup>179</sup> In granulocytopenic patients, it usually involves the lung and causes high mortality rates. The clinical presentation is difficult to distinguish from invasive pulmonary aspergillosis.<sup>180,181</sup> A so-called reversed halo sign has been described on computed tomography scans, but is not entirely specific for mucormycosis.<sup>182-184</sup> Such ring-shaped consolidation surrounding a central infiltrate should prompt a diagnostic work-up including bronchoalveolar lavage and biopsy.<sup>8,185</sup>

Treatment combines surgical debridement and antifungal treatment (AII). Surgery is often necessary to confirm diagnosis and may be used to decrease the fungal burden.<sup>3,186</sup>

For first-line antifungal treatment, options include a lipid-based amphotericin B formulation, isavuconazole or posaconazole.<sup>3,53,186,187</sup> D-AmB yielded inferior results, is nephrotoxic and the AGIHO discourage the use of D-AmB<sup>188</sup> (DI). ABLC treatment was published in small series only,<sup>188,189</sup> while there are a larger

number of reports including one series of L-AmB treatment (up to 10 mg/kg/d iv) for mucormycosis.<sup>190-193</sup> Posaconazole has been studied primarily for second-line or salvage therapy in small case series but not for first-line treatment.<sup>48,194-196</sup> Isavuconazole has been studied in a single-arm open-label trial (VITAL study) in 37 patients for a median of 84 days.<sup>187</sup> Day-42 crude all-cause mortality was 33% and efficacy was found similar to amphotericin B. See Table 5a,b.

In a small series, antifungal combination therapy has been reported. Posaconazole plus L-AmB (either 3 mg/kg or 5 mg/kg) has been successfully used in 27 patients.<sup>197</sup> L-AmB has been successfully combined with caspofungin for rhino-orbital-cerebral diseases in mostly diabetic non-cancer patients<sup>198</sup> (CIII). In an animal model, the combination of isavuconazole and micafungin did not show an additive effect as compared to isavuconazole alone.<sup>199</sup>

In second-line treatment, the same drugs were used either for refractory disease or because of intolerance of the patient, that is ABLC,<sup>200</sup> L-AmB,<sup>201</sup> ABCD<sup>202</sup> or posaconazole.<sup>48,186,195</sup>

Voriconazole is inactive in mucormycosis, and breakthrough infections during voriconazole exposure have been reported from retrospective evaluations and various case reports.<sup>109,203-206</sup> However, prospective clinical trials on voriconazole prophylaxis did not confirm an increased incidence.<sup>207-209</sup>

**Recommendation:** In summary, most data, including results of multivariate prognostic factor analyses, support the use of L-AmB 5 mg/kg/d (AII), and doses >5 up to 10 mg/kg/d (AII), while isavuconazole (200 mg/d) and posaconazole (4 × 200 mg/d) are recommended with lesser strength (BIII) in the first-line treatment. Second-line treatment with isavuconazole (AIII) or posaconazole is recommended (AIII), while all three lipid-based amphotericin B formulations are alternatives (BIII). The use of D-AmB is discouraged (DI). Surgical resection of the fungal disease focus is recommended (AII). Combination therapy has not been studied properly but the use of L-AmB plus posaconazole was promising (BIII) as well as L-AmB plus caspofungin in non-cancer patients (CIII).

## 4.5 | Treatment of cryptococcosis

The vast majority of clinical studies on treatment of cryptococcosis have been performed in patients with HIV infection/ AIDS (mostly in Africa), albeit patients with idiopathic CD4 lymphocytopenia and haemato-oncological malignancies might also be affected.<sup>210-213</sup> Infections by *Cryptococcus* spp.—mainly *C. neoformans* or *C. gattii*—commonly involve the CNS, but pulmonary disease, fungemia or disseminated infections might also occur.<sup>210,214,215</sup> Diagnosis is usually based on fungal cultures, India ink smear examination, latex-antigen test and PCR studies using cerebrospinal fluid. Because cryptococcosis is relatively rare in cancer patients, recommendations on treatment are transferred from studies in patients with HIV/ AIDS. In order to be consistent with other guidelines of the AGIHO, we recommend the use of L-AmB and the use of D-AmB is discouraged, primarily due to toxicity concerns.<sup>216-218</sup> Data from

**TABLE 5** Recommendations for specific invasive fungal diseases incl. therapeutic drug monitoring. Mucormycosis—(a) first-line therapy and (b) second-line/salvage therapy

(a) Population	Intention	Intervention	SoR	QoE	Reference
Any	To cure	Additional surgery (in combination with antifungal therapy)	A	II	(345-347)
Any	To cure	Liposomal amphotericin B	A	II	(190,191,193,345,346)
Any	To cure	Isavuconazole	B	IIu	(187)
Any	To cure	Posaconazole	B	IIu	(191,346)
Any	To cure	Combination L-AmB + caspofungin L-AmB + posaconazole	C B	III IIu	(197,198)
Any	To cure	Amphotericin B lipid complex	D	II	(200) (348)
Any	To cure	Amphotericin B formulation + deferasirox	D	II	(349)
Any	To cure	Amphotericin B deoxycholate	D	I	(338)
(b) Population	Intention	Intervention	SoR	QoE	Reference
Any	To cure	Isavuconazole	A	IIh	(187)
Any	To cure	Posaconazole	A	IIu	(195) (48) (194)
Any	To cure	Liposomal amphotericin B	B	IIu	(201)
Any	To cure	Amphotericin B formulation + posaconazole combination	B	IIu	(197)
Any	To cure	Amphotericin B lipid complex	B	II	(200) (348)
Any	To cure	combination Caspo/L-Amb	C	III	(198)
Any	To cure	Amphotericin B deoxycholate	D	I	(338)

clinical studies are rare in cancer patients as compared to patients with HIV/AIDS where the combination of D-AmB plus flucytosine is regarded as standard treatment.<sup>219,220</sup> Treatment of CNS cryptococcosis in haematological patients should comprise L-AmB together with flucytosine (5-FC) (AIIt),<sup>221-223</sup> usually followed by maintenance therapy with fluconazole.<sup>215,217,218</sup> Alternatively, a combination of L-AmB plus fluconazole or voriconazole might be used, if flucytosine is not available (BIIt).<sup>224-226</sup> Recently, an induction therapy with a single, high-dose L-AmB given with high-dose fluconazole and flucytosine was shown not to be inferior to a standard seven-day course of D-AmB plus flucytosine in HIV patients.<sup>227</sup> See Table 6a-c.

Second-line or salvage treatment options for CNS cryptococcosis include L-Amb as single agent (BIIt), ABLC (BIIt), voriconazole (BIIt,u), posaconazole (CIII), isavuconazole (CIII), D-AmB combined with voriconazole or fluconazole (BIIt).<sup>218,224-226,228-232</sup> Severe cryptococcosis of the lungs or of other organ systems should be treated like CNS cryptococcosis (CIII). Monotherapy with fluconazole is less effective, and the use of this monotherapy is strongly discouraged (DI).<sup>233</sup> Echinocandins (eg anidulafungin, caspofungin or micafungin) are not active against *Cryptococcus* spp. In vitro, and breakthrough disseminated cryptococcal disease has been reported.<sup>234,235</sup> Therefore, echinocandins should not be used for treatment of cryptococcosis (DI).

*Recommendation:* Treatment of CNS cryptococcosis in haematological patients should comprise L-AmB instead of D-AmB) together with flucytosine (5-FC) followed by maintenance therapy with fluconazole (AIIt). Second-line or salvage treatment options for CNS cryptococcosis include L-Amb as single agent (BIIt), ABLC (BIIt), voriconazole (BIIt,u), posaconazole (BIII), isavuconazole (BIII), L-AmB combined with voriconazole or fluconazole (BIIt).

#### 4.6 | Treatment of fusariosis

Invasive fusariosis is a severe sporadic mold infection affecting mainly granulocytopenic patients.<sup>236,237</sup> It is associated with a very high mortality rate ranging from 50% to 80%.<sup>236,238,239</sup> Recovery from granulocytopenia is most critical for a response to antifungal therapy.<sup>240,241</sup> The skin and the lungs are the most frequent sites of infection, albeit involvement of the sinuses, soft tissues and fungemia or disseminated infections occur frequently.<sup>236,242,243</sup> Systematic prospective analyses on the treatment of fusarium infections are still lacking. L-AmB and Voriconazole has been used successfully within the last years to treat invasive fusariosis (BIIt).<sup>132,236,244,245</sup> In severely ill patients, combination therapy with L-AmB plus voriconazole may be an effective alternative (BIII).<sup>245,246</sup> Posaconazole (BIII) or ABLC (BIII) might be used as alternative treatment options.<sup>189,200,236,247</sup>



**TABLE 6** Recommendations for specific invasive fungal diseases incl. therapeutic drug monitoring. Cryptococcal meningoenkephalitis—(a) first-line therapy, (b) salvage/second-line therapy and (c) adjunct/non-medical therapy

(a) Clinical situation	Intention	Intervention	SoR	QoE	Comments	References	
Cryptococcal meningoenkephalitis	To cure/improve outcome	Induction: L-Amb + 5-FC ≥2-6 wk	A	III	Duration of induction dependant on the degree of immunosuppression (eg, SOT vs others)	(218,220,230,350)	
		Consolidation: FLU 400-800 mg 2 wk					
		Maintenance: FLU 200 mg ≥ 1 y					
		L-Amb/D-Amb + Vori or Flu	B	III,(r)	Might be used if 5-FC is not available, but could produce inferior outcomes	(224,230,351) (225)	
		L-Amb/ABLC	B	III		(218,232,352-357)	
		Fluconazole	D	I	High relapse rate	(233)	
		Echinocandins	D	III	No in vitro activity		
(b) Clinical situation	Intention	Intervention	SoR	QoE	References		
Cryptococcal meningoenkephalitis	To cure/improve outcome	Voriconazole	B	III,u		(132,226,358,359) (360)	
		Posaconazole	B	III		(228,229)	
		Isavuconazole	B	III		(231)	
		Flu + 5-FC	C	III		(215,361)	
		Fluconazole (single agent)	D	III,u		(361-363)	
		L-Amb/D-Amb + Vori or Flu	B	III,(r)		(224,225,230,351)	
(c) Clinical situation	Intention	Intervention	SoR	QoE	Comments	References	
Cryptococcal meningoenkephalitis	To reduce ICP/to cure	Therapeutic LP	B	III,u,t	Measure ICP at baseline, Mainly useful for elevated ICP (>250 mm H <sub>2</sub> O) or new symptoms	(210,364)	
		Involve ID specialist	B	III,u,t	Adhere to established guidelines	(365)	
	To enhance guideline adherence/improve outcome	Sertraline	D	III,u,t	Sertraline did not reduce mortality in AIDS patients	(366)	
		Maintain CNI	C	III	Data from SOT patients	(367)	
	To reduce disabilities/to cure	Dexamethasone	D	III	Might be useful occasionally, but avoid general use of dexamethasone	(215) (368)	

However, breakthrough *Fusarium* IFDs have been reported while on posaconazole prophylaxis.<sup>24,248</sup> Clinical data on the efficacy of isavuconazole are lacking. For bridging of neutrophil recovery, granulocyte transfusion has been successfully used in persistently granulocytopenic patients in addition to AFT<sup>249</sup> (CIII). Surgical resection of necrotic tissues (eg skin), central venous line removal and in vitro resistance testing might be further measures to improve the outcome of patients with invasive fusariosis<sup>241,243,250</sup> (BIII).

**Recommendation:** For first-line therapy, L-AmB or voriconazole should be used (BII). In severely ill patients, combination therapy with L-AmB plus voriconazole may be an effective alternative (BIII). Posaconazole (BIII) or ABLC (BIII) might be used as alternative treatment options or for salvage therapy. For more detailed information, the reader is referred to the detailed ESCMID/ ECMM guideline.<sup>247</sup>

#### 4.7 | Treatment of trichosporonosis

*Trichosporon* species underwent various reclassification in taxonomic assignments, because it became apparent that these are genetically heterogeneous.<sup>251,252</sup> *Trichosporon capitatum* has been renamed to *Geotrichum capitatum* in the past, and later to *Blastoschizomyces capitatus* and is now called *Magnusiomyces capitatus* because it belongs to a different genera other than *Trichosporon*.<sup>251</sup> However, cases of invasive trichosporonosis often comprise infections with *Trichosporon* spp. and/or *Geotrichum capitatum* together, which makes it difficult to give clear recommendations.<sup>253</sup> Trichosporonosis may occur either as superficial or invasive mycosis.

Fungemia (often CVC-related fungemia) and disseminated IFDs in immunocompromised patients have been mostly reported due to *Trichosporon sahaii*, but invasive IFDs due to *Trichosporon mucoides* or *Trichosporon asteroides* have all been reported.<sup>252,254-256</sup> Following infections with *Trichosporon* spp., appearance of hepatic and splenic lesions with the recovery from granulocytopenia has been described similar to IRIS in disseminated candidosis.<sup>257</sup> Treatment of invasive trichosporonosis remains a challenge, and no data from prospective trials are available. High fatality rates were reported from granulocytopenic patients with acute leukaemia (crude mortality up to 77%).<sup>253,256</sup> Response to D-AmB was reported to be poor in 55 patients from Italy (response in 24% of patients).<sup>253</sup> *Trichosporon asahii* isolates exhibit often high MICs to Amphotericin B in vitro. Therefore, D-AmB cannot be recommended for first-line monotherapy (DIII). Echinocandins exhibit no in vitro activity against *Trichosporon* spp. and should not be used (DIII).<sup>252</sup> Breakthrough trichosporonosis has been repeatedly reported in patients with haematological malignancies receiving micafungin but also rarely on D-AmB and azole therapy (eg during prophylaxis with itraconazole or posaconazole).<sup>256,258-261</sup>

Response to AFT and survival was best when patients receive azole therapy (fluconazole, voriconazole) (CIII).<sup>262,263</sup> Several case reports support the first-line use of voriconazole (BIII) in patients with haematological malignancies even in disseminated IFD (including CNS) or after itraconazole prophylaxis.<sup>255,259,264-267</sup> However,

occurrence of multi-drug and pan-azole resistant *Trichosporon* isolates have been reported.<sup>268,269</sup> Combination therapy of voriconazole and L-AmB and even caspofungin plus L-AmB were reported to be effective in some case reports.<sup>270,271</sup> Due to the poor prognosis of invasive trichosporonosis, combination therapy is frequently used, but data are not sufficient to establish a recommendation for the use of any combination.<sup>259</sup>

**Recommendation:** For first-line therapy, use of voriconazole is recommended (BIII) in patients with haematological malignancies. Combination therapy of voriconazole and L-AmB or caspofungin plus L-AmB has been reported in case reports, but data are insufficient to give recommendations. Occurrence of multi-drug and pan-azole resistant *Trichosporon* isolates has been reported which support in vitro susceptibility testing of the fungal isolate. For more detailed information, the reader is referred to the detailed ESCMID/ ECMM guideline.<sup>272</sup>

#### 4.8 | Treatment of scedosporidiosis

*Scedosporium* species are opportunistic fungal species causing life-threatening disseminated infections in immunocompromised patients.<sup>247,273-275</sup> Disseminated infections afflicted primarily individuals with haematological malignancies, and IFD is often fatal in this patient group (mortality rate up to 87.5%).<sup>275-277</sup>

The most common pathogens are *Lomentospora prolificans* (formerly *Scedosporium prolificans*) and *Scedosporium apiospermum* (formerly *Pseudallescheria boydii*).<sup>273</sup> While *L. prolificans* typically occur in immunocompromised patients, *S. apiospermum* is often reported in immunocompetent individuals after near-drowning.<sup>241</sup> Systemic infections with *Scedosporium* species are often refractory to treatment as these pathogens are highly resistant to most available antifungal agents.<sup>278-280</sup> Patients with disseminated *L. prolificans* infection often have positive blood culture (up to 70%).<sup>281</sup> However, most blood cultures become positive shortly before death and antifungal therapy often failed in the terminally ill patient.<sup>241,275</sup> Malignancy, fungemia, CNS and lung involvement predicted a adverse outcome.<sup>281</sup> According to a multivariate analysis of 162 cases, survival was independently associated with surgical excision and recovery from aplasia but not from antifungal therapy (not specified).<sup>275</sup> No treatment data from randomised trials exist for any patient group, and available information about treatment outcomes is available only from case reports and case collections. According to a large registry with 264 cases, patients treated with voriconazole had a better outcome compared to treatment with amphotericin B formulations.<sup>281</sup>

Voriconazole has better in vitro activity against *S. apiospermum* as compared to *L. prolificans* and is regarded as drug of choice for disseminated scedosporidiosis (BII).<sup>280,282</sup> Other azoles such as posaconazole or isavuconazole do have similar in vitro activity against *S. apiospermum* compared to voriconazole and might serve as alternatives.<sup>283</sup> The clinical activity of D-AmB and/ or L-AmB is unclear in granulocytopenic patients and cannot be currently recommended

(DIII). In a small case series of 25 patients, the majority of survivors received a combination therapy consisting of L-AmB and a triazole (voriconazole, posaconazole).<sup>277</sup> Given these data, the treatment recommendation for *S apiospermum* infection is an azole such as voriconazole or posaconazole plus surgical debridement (BIII).

Results from in vitro testing found a synergistic effect in the combination of voriconazole plus terbinafine against *L proliferans*.<sup>284</sup> This in vitro effect was translated into clinical practice, showing a response in some patients with clearance of disseminated *L proliferans* infection.<sup>285-289</sup> The combination of azoles plus echinocandin revealed conflicting results and clinical data are lacking (DIII). In an in vitro study, the azole/echinocandin (micafungin) combination did not show a better in vitro activity when compared to voriconazole or posaconazole monotherapy.<sup>290</sup> However, in an animal model micafungin combined with voriconazole or amphotericin B was effective in reducing fungal burden and prolonging survival.<sup>291</sup> As a potential option serves the combination of voriconazole with miltefosine which showed synergy against *L proliferans* isolates in vitro and was successfully used in a child with refractory *L proliferans* osteomyelitis.<sup>292,293</sup>

**Recommendation:** Taken together, voriconazole plus terbinafine appears to be the best currently available treatment for invasive scedosporidiosis in patients with haematological malignancies (CIII). For more detailed information the reader is referred to the detailed ESCMID/ECMM guideline.<sup>247</sup>

#### 4.9 | Therapeutic drug monitoring of antifungal agents

Pharmacokinetic properties of antifungal agents vary substantially, and bioavailability might have an impact on clinical efficacy. For flucytosine with its known association of plasma concentrations with toxicity, therapeutic drug monitoring (TDM) has broadly been established.<sup>147,294,295</sup> For flucytosine, a plasma target concentration of 30-80 mg/mL two hours after application is recommended (BIIt). For azole antifungal drugs, therapeutic drug monitoring (TDM) has been frequently studied to guide AFT, especially to avoid toxicity.<sup>59,63,296,297</sup>

Voriconazole plasma concentrations show a broad range of intra- and interindividual variation.<sup>60,63,298,299</sup> In recipients of an allogeneic HSCT, exposure and clearance of voriconazole are similar to those of healthy volunteers though there was high intra- and interindividual variation in drug exposures.<sup>300</sup> This is caused by potential drug interactions due to metabolism through the cytochrome P450 system, altered biodegradation due to genetic variations of isoenzyme CYP2C19 and other factors including food, co-medication and absorption.<sup>60,297,298,301</sup> In consequence, voriconazole plasma concentrations cannot be predicted by dosage.<sup>60,63,302</sup> According to a recent meta-analysis, patients with therapeutic voriconazole serum concentrations were twice as likely to achieve successful outcomes.<sup>60,63,298</sup> An increased rate of adverse events with high plasma concentrations (usually above 5.0-5.5 mg/L) has been reported.<sup>57,60,298</sup> With regard to efficacy, the serum level should exceed 1-2 mg/L, while one study found a significantly higher treatment failure rate when voriconazole levels were <1.7 mg/L as compared to >1.7 mg/L.<sup>57,302</sup> Multiple regression analyses of voriconazole concentration identified associations of increasing patient weight, oral administration of voriconazole, and coadministration of phenytoin or rifampin with significantly reduced concentrations, and associations of advanced patients age and coadministration of proton-pump inhibitors with increased concentrations.<sup>57</sup>

Therefore, with regard to safety and efficacy TDM in patients treated with voriconazole is generally recommended (BIIr) and plasma concentrations between 2 and 5 mg/L are considered as adequate.<sup>57,303</sup> Plasma levels should be measured 2-5 days after initiation of therapy and should be monitored weekly until achievement of stable steady state levels.

Posaconazole is meanwhile available intravenously and in different oral formulation.<sup>41,49</sup> In patients treated with oral suspension, absorption is limited and daily doses above 800 mg daily did not increase plasma concentration.<sup>304</sup> Drug interactions, fasting condition and increased gastric pH, for example due to proton-pump inhibitor usage, may impair bioavailability<sup>305</sup> in AML/MDS patients. Patient weight, presence of diarrhoea, and concomitant medications (chemotherapy and pantoprazole) showed significant effects on posaconazole exposure.<sup>306</sup> A retrospective analysis in patients

**TABLE 7** Recommendations for specific invasive fungal diseases incl. therapeutic drug monitoring. Therapeutic drug monitoring (TDM)

Intention	Drug	SoR	QoE	Comment	Reference
Definition of serum levels for optimal therapy	Posaconazole	B	IIt/r	<ul style="list-style-type: none"> <li>700-1830 ng/mL (prophylaxis)</li> <li>800-2100 ng/mL (prophylaxis and therapy)</li> <li>&gt;1 mg/L (therapy)</li> </ul>	(105) (40,307)
	Voriconazole	B	IIr	<ul style="list-style-type: none"> <li>2-5 mg/L</li> <li>sustained high concentration associated with hepatotoxicity</li> </ul>	(57,303)
	Isavuconazole	C	III (not yet well defined)	<ul style="list-style-type: none"> <li>2-4 mg/L</li> </ul>	(311,369)
	Flucytosine	B	IIt	<ul style="list-style-type: none"> <li>30-80 mg/mL</li> </ul>	

**Note:** Determination of plasma/serum concentrations of Vori/Posa should be considered at least in case of (a) Suspected breakthrough infection. (b) (suspected) insufficient response, despite sufficient therapy (dose, duration  $\geq 2$  wk). (c) Suspected drug related toxicity. (d) Switch from iv to oral therapy. (e) Limited oral resorption (nausea, diarrhoea etc). (f) Specific comedications (z.B. PPI).

receiving posaconazole prophylaxis showed an association with drug plasma levels and breakthrough IFD as well as with clinical outcome.<sup>307</sup> Another retrospective study included patients with both prophylaxis and therapy with posaconazole and showed that higher serum levels correlate with an improved outcome. Therefore, TDM in patients treated with posaconazole suspension is generally recommended with target levels above 1 mg/L during antifungal therapy (BIIR).<sup>56</sup> However, due to the fact that the tablet formulation of posaconazole is less affected by altered absorption and is associated with higher and more stable plasma concentration use of the tablet formulation instead of the suspension is generally recommended.<sup>308</sup> Of note, in patients with haematological malignancies receiving either posaconazole tablets or posaconazole iv for prophylaxis all breakthrough IFDs were observed with posaconazole levels above 0.7 mg/l.<sup>105</sup> Despite the use of posaconazole tablets, alterations of drug plasma concentrations were reported in patients suffering from diarrhoea or under treatment for graft-vs-host disease.<sup>309,310</sup> TDM is recommended in patients treated with posaconazole tablets or suspension (BIIR).

Only limited data are available for the use of TDM in patients treated with isavuconazole.<sup>311</sup> Population pharmacokinetics from clinical trials (SECURE trial, VITAL study) did not show a significant relationship between drug exposure and efficacy endpoints<sup>311,312</sup> suggesting that routinely TDM of isavuconazole may not be generally necessary. However, TDM may be indicated in the setting of treatment failure, suspected drug interactions or toxicity. Plasma concentrations between 2 and 4 mg/L are considered as adequate (CIII). A potential threshold for toxicity (mainly gastrointestinal) was observed in patients during therapy with isavuconazole with serum concentrations exceeding 4.8 mg/L.<sup>313</sup> However, therapeutic target levels are not well defined. For polyenes (D-AmB and AmB formulations) or echinocandins (anidulafungin, caspofungin, micafungin), there is no clear evidence to support routine use of TDM in cancer patients (DI).

**Recommendation:** In summary, TDM for triazoles can be used to improve clinical response and to avoid toxicity (BIIRt). Determination of plasma/serum concentrations of voriconazole and posaconazole should be considered at least in case of suspected breakthrough infections, a lack of response despite sufficient antifungal chemotherapy (adequate dosage, duration  $\geq 2$  weeks), suspected drug-related toxicity, switch from intravenous to oral therapy, oral therapy and limited resorption because of nausea or diarrhoea or specific co-medications (eg proton-pump inhibitor in case of posaconazole). For voriconazole, a plasma concentration between 2 and 5 mg/L and for posaconazole above 0.7 mg/L (for prophylaxis) and 1 mg/L (for therapy) should be targeted for therapy of invasive fungal infection (BIIRt/r). Although optimal timing and quantity of determined plasma concentrations have not been sufficiently investigated, trough concentrations in steady state might be appropriate (CIII). For flucytosine, a plasma target concentration of 30-80 mg/mL two hours after application is recommended (BIIRt). See Table 7.

## 4.10 | Interventional strategies

### 4.10.1 | Surgical intervention

Potential indications for a surgical intervention in pulmonary fungal infection might be<sup>314</sup>: (a) acute haemoptysis, (b) need of histological diagnostics, (c) removal of residual infiltrates prior to the subsequent chemotherapy, (d) prevention of haemorrhage in the case of fungal lesions with vessel involvement, and (e) reduction of fungal burden (eg in mucormycosis). However, due to improved diagnostics and frequent use of empirical and/or pre-emptive antifungal therapy a decline in the use of surgical biopsy for diagnosis of pulmonary IFD has evolved in recent years.<sup>315</sup>

Haemoptysis occurs in pulmonary aspergillosis or mucormycosis in up to 30% of the cases, frequently during the phase of neutrophil recovery. The resection of residual infiltrations, combined with antifungal therapy, may result in a local control of the fungal infection in patients requiring further intensive chemotherapy or transplantation.<sup>316-318</sup> Peri- and postsurgical intervention-associated mortality was described as low (<10%) in most but not all studies, but biopsies lead to a high diagnostic yield for fungal identification.<sup>319,320</sup> Fungal infections were cleared in the majority of patients, particularly when only a single lesion was present.<sup>317</sup> Due to limited data, it is challenging to define a subgroup of patients with IPA who most likely benefit from lung resection. With the use of new broad-spectrum antifungal agents, surgical resection of pulmonary lesions is recommended when patient do not respond to first-line therapy in accordance to the ESCMID guideline<sup>5</sup> (BII). In patients with life-threatening haemoptysis, emergency surgical intervention may be helpful for bridging until neutrophil recovery (BIIR).<sup>5</sup> In suspected or proven CNS aspergillosis surgical resection (together with AFT using voriconazole or isavuconazole) should be considered in order to improve survival rate (AII).<sup>118,119</sup> In sinu-nasal aspergillosis, additional surgical intervention should be considered to cure the IFD in individual cases (AIII).

### 4.10.2 | Drug instillation

For treatment of refractory abscesses, cavities (eg in the lung) or severe haemoptysis from pulmonary aspergilloma in which surgical intervention is not feasible, a drainage (in particular for fungal empyema) as well as a local drug instillation may be considered.<sup>321,322</sup> Here, antifungal preparations (commonly containing AmB preparation or azoles, eg voriconazole) have been used (CIII).<sup>323-325</sup> No change to previous AGIHO recommendations.

### 4.10.3 | Embolisation

Embolisation may be considered in the case of large pulmonary infiltrates where the occurrence of severe haemoptysis due to vessel erosion is likely, including the development of aneurysms.<sup>326</sup> The use

of CT perfusion (by computed tomography pulmonary angiography) in case of suspicion of angioinvasive pulmonary mycosis proved beneficial and could discriminate from other pulmonary infections.<sup>327</sup> In this case, the bronchial and pulmonary vessels may be embolised (CIII). No change to previous AGIHO recommendations.

#### 4.11 | Immunotherapy and granulocyte transfusion

*Colony-stimulating factors:* The application of haematopoietic growth factor should be considered on an individual case-by-case basis, according to the recommendations of the EORTC (B III).<sup>328</sup> A study from Italy showed a more rapid reduction in the galactomannan antigen titre and a better outcome in patients with IPA after haplo-identical stem cell transplantation, when receiving T cells were raised against fungal pathogens.<sup>329</sup> Further studies with the transfer of immune-effector cells and better tools to determine the numbers of fungus-specific T cells prior and after cellular immunotherapy are required. So far, this type of therapeutic intervention is still considered experimental.

*Granulocyte transfusions:* Compared to the 1980s, granulocyte harvest and granulocyte function have clearly improved by stimulating donors with G-CSF.<sup>330,331</sup> Presently, interventional granulocyte transfusions are being studied in clinical trials.<sup>331</sup> In a retrospective case-controlled study on 74 stem cell transplant patients, there was a tendency toward worse outcome in the transfused patients.<sup>332</sup> Another case-controlled study in patients with candidemia showed an equal short-term survival rate, but the group with granulocyte transfusions had higher risk factors which may be interpreted as a benefit of this option.<sup>333</sup> In 31 patients with invasive fungal infection (17 possible infections) undergoing granulocyte transfusions, 78% survived.<sup>334</sup> A randomised study with prophylactic granulocyte transfusion three times a week in patients with granulocytopenic fever and pulmonary infiltrates or a history of proven IFD failed to confirm the benefit of this procedure.<sup>335</sup> Currently, a clear benefit of granulocyte transfusions in IFDs has not been proved.<sup>336</sup> However, it might be considered as a treatment option in selected patients (CIII).

#### CONFLICT OF INTEREST

NA received honoraria for lectures from Basilea Pharmaceutica; honoraria for advice from Gilead, MSD Sharp & Dohme GmbH, Pfizer and Amgen; and travel grant from Gilead, MSD Sharp & Dohme GmbH, Pfizer and Amgen. BB reported no conflict of interest in this context. MC received Honoraria MSD, Gilead, Shionogi, Basilea, Pfizer, Jazz and Amgen. DB is consultant to Gilead Sciences; received research grants from Gilead Sciences and Pfizer; served on the speakers' bureau of Gilead Sciences, Merck Sharp & Dohme/Merck, and Pfizer; and received travel grants from Merck Sharp & Dohme/Merck and Pfizer. OAC is supported by the German Federal Ministry of Research and Education and the European Commission and has received research grants from, is an advisor to, or received lecture honoraria from Actelion, Allegra Therapeutics, Amplex, Astellas, Basilea,

Biosys UK Limited, Cidara, Da Volterra, Entasis, F2G, Gilead, Grupo Biotoscana, Janssen Pharmaceuticals, Matinas, Medicines Company, MedPace, Melinta Therapeutics, Menarini Ricerche, Merck/MSD, Octapharma, Paratek Pharmaceuticals, Pfizer, PSI, Rempex, Scynexis, Seres Therapeutics, Tetrphase and Vical. JH was a consultant to Incyte, Jazz, MSD, AbbVie, Roche, AMGEN, Pfizer, BMS, Gilead and Celgene and received travel grants from Neovii. WJH received research grants from MSD Sharp & Dohme/Merck and Pfizer; serves on the speakers' bureaus of Alexion, Astellas, Basilea, Bristol-Myers Squibb, Gilead Sciences, Janssen, MSD Sharp & Dohme, and Pfizer; and received travel grants from Alexion, Astellas, Lilly, MSD Sharp & Dohme, Novartis and Pfizer. MH served on advisory boards of Amgen, BMS, Hexal, Janssen, Jazz Pharma, Roche, Sanofi and Takeda; served on the speakers' bureau of Amgen, BMS, Celgene, Janssen, Sanofi and Takeda; and received travel grants from Amgen, Celgene, Janssen and Takeda. MKo received lecture honoraria from Biotest and travel grants from Biotest and JAZZ Pharmaceuticals. MKa reported no conflict of interest in this context. GM received honoraria for lectures from Gilead. JP has received personal fees (speaker, advisory board membership honoraria, or both) from Alexion, BMS, Boehringer-Ingelheim, Grünenthal, MSD, Novartis, Pfizer, Chugai, Roche and Apellis. OP received research grants from Bio-Rad and Gilead; is consultant to Merck/MSD and Gilead; and received lecture honoraria and travel grants from Astellas, Gilead, Pfizer, and Merck/MSD. MR was a consultant to Basilea, Daiichi Sankyo, Kedplasma, Janssen, and Scynexis and received payment for development of educational presentations from Basilea and Janssen. JS received research grants from Astra Zeneca, Essai and Novartis and received personal fees (speaker, advisory board membership honoraria, or both) from Pfizer, Ipsen, MSD, Takeda, Novartis, Celgene and Janssen. MSH received travel support from the AGIHO/DGHO. SS has received personal fees (speaker, advisory board membership honoraria, or both) and travel grants from Amgen, Basilea, BTG International Inc, Gilead, Jazz Pharmaceuticals, Merck/MSD and Pfizer, and has served as consultant to Amgen. DT received honoraria and travel grant from Gilead, Pfizer, and MSD; travel grant from Abbvie, Astellas, Celgene and Jazz; and served as consultant of advisory board for Gilead, MSD and Pfizer. MvLT is supported by the German Federal Ministry of Research and Education (BMBF grants 01EO1002 and 13GW0096D); has received research grants from Pfizer, Gilead and MSD, is a consultant to Merck/MSD and Gilead; and received honoraria or travel grants from Basilea, Gilead, Merck/MSD, and Astellas. AJU reports grants and personal fees from MSD and personal fees from Gilead, Pfizer and Astellas. MJGTV has served at the speakers' bureau of Akademie für Infektionsmedizin, Ärztekammer Nordrhein, Astellas Pharma, Basilea, Gilead Sciences, Merck/MSD, Organobalance, Uniklinik Freiburg/ Kongress und Kommunikation and Pfizer, received research funding from 3M, Astellas Pharma, DaVolterra, Gilead Sciences, MaaT Pharma, Merck/MSD, Morphochem, Organobalance, Seres Therapeutics, and is a consultant to Alb-Fils Kliniken GmbH, Ardeypharm, Astellas Pharma, Berlin Chemie, DaVolterra, Ferring, MaaT Pharma and Merck/MSD. FW reported no conflict of interest in this context.



## AUTHOR CONTRIBUTIONS

**Markus Ruhnke:** Conceptualization (Lead); Data curation (Lead); Formal analysis (Lead); Methodology (Lead); Project administration (Lead); Resources (Lead); Supervision (Lead); Writing – original draft (Lead); Writing – review and editing (Lead). **Oliver Cornely:** Conceptualization (Equal); Methodology (Equal); Project administration (Equal); Writing – review and editing (Equal). **Martin Schmidt-Hieber:** Writing – review and editing (Equal). **Nael Alakel:** Writing – review and editing (Equal). **Boris Boell:** Writing – review and editing (Supporting). **Dieter Buchheidt:** Writing – review and editing (Supporting). **Maximilian Christopeit:** Writing – review and editing (Supporting). **Justin Hasenkamp:** Writing – review and editing (Supporting). **Werner Heinz:** Writing – review and editing (Supporting). **Marcus Hentrich:** Writing – review and editing (Supporting). **Meinolf Karthaus:** Formal analysis (Supporting); Project administration (Supporting); Writing – review and editing (Equal). **Michael Koldehoff:** Writing – review and editing (Supporting). **Georg Maschmeyer:** Formal analysis (Equal); Project administration (Equal); Writing – review and editing (Equal). **Jens Panse:** Writing – review and editing (Supporting). **Olaf Penack:** Writing – original draft (Equal); Writing – review and editing (Equal). **Jan Schleicher:** Writing – review and editing (Supporting). **Daniel Teschner:** Writing – review and editing (Supporting). **Maria Vehreschild:** Writing – review and editing (Supporting). **Marie von Lilienfeld-Toal:** Methodology (Equal); Writing – original draft (Equal); Writing – review and editing (Equal). **Florian Weissinger:** Writing – review and editing (Supporting). **Stefan Schwartz:** Writing – original draft (Equal); Writing – review and editing (Equal).

## ORCID

Markus Ruhnke  <https://orcid.org/0000-0002-0793-9729>

Oliver A. Cornely  <https://orcid.org/0000-0001-9599-3137>

Werner J. Heinz  <https://orcid.org/0000-0002-7833-9202>

## REFERENCES

- Pagano L, Caira M, Offidani M, et al. Adherence to international guidelines for the treatment of invasive aspergillosis in acute myeloid leukaemia: feasibility and utility (SEIFEM-2008B study). *J Antimicrob Chemother.* 2010;65(9):2013-2018.
- Moussat S, Buchheidt D, Heinz W, et al. Treatment of invasive fungal infections in cancer patients—updated recommendations of the Infectious Diseases Working Party (AGIHO) of the German Society of Hematology and Oncology (DGHO). *Ann Hematol.* 2014;93(1):13-32.
- Cornely OA, Arikian-Akdagli S, Dannaoui E, et al. ESCMID and ECMM joint clinical guidelines for the diagnosis and management of mucormycosis 2013. *Clin Microbiol Infect.* 2014;20(Suppl 3):5-26.
- Cornely OA, Bassetti M, Calandra T, et al. ESCMID\* guideline for the diagnosis and management of Candida diseases 2012: non-neutropenic adult patients. *Clin Microbiol Infect.* 2012;18(Suppl 7):19-37.
- Ullmann AJ, Aguado JM, Arikian-Akdagli S, et al. Diagnosis and management of Aspergillus diseases: executive summary of the 2017 ESCMID-ECMM-ERS guideline. *Clin Microbiol Infect.* 2018;24(Suppl 1):e1-e38.
- Ullmann AJ, Akova M, Herbrecht R, et al. ESCMID\* guideline for the diagnosis and management of Candida diseases 2012: adults with haematological malignancies and after haematopoietic stem cell transplantation (HCT). *Clin Microbiol Infect.* 2012;18(Suppl 7):53-67.
- Mellinghoff SC, Panse J, Alakel N, et al. Primary prophylaxis of invasive fungal infections in patients with haematological malignancies: 2017 update of the recommendations of the Infectious Diseases Working Party (AGIHO) of the German Society for Haematology and Medical Oncology (DGHO). *Ann Hematol.* 2018;97(2):197-207.
- Maschmeyer G, Carratala J, Buchheidt D, et al. Diagnosis and antimicrobial therapy of lung infiltrates in febrile neutropenic patients (allogeneic SCT excluded): updated guidelines of the Infectious Diseases Working Party (AGIHO) of the German Society of Hematology and Medical Oncology (DGHO). *Ann Oncol.* 2015;26(1):21-33.
- Heinz WJ, Buchheidt D, Christopeit M, et al. Diagnosis and empirical treatment of fever of unknown origin (FUO) in adult neutropenic patients: guidelines of the Infectious Diseases Working Party (AGIHO) of the German Society of Hematology and Medical Oncology (DGHO). *Ann Hematol.* 2017;96(11):1775-1792.
- Chen K, Wang Q, Pleasants RA, et al. Empiric treatment against invasive fungal diseases in febrile neutropenic patients: a systematic review and network meta-analysis. *BMC Infect Dis.* 2017;17(1):159.
- Fung M, Kim J, Marty FM, Schwarzing M, Koo S. Meta-analysis and cost comparison of empirical versus pre-emptive antifungal strategies in hematologic malignancy patients with high-risk febrile neutropenia. *PLoS ONE.* 2015;10(11):e0140930.
- Aguado JM, Vazquez L, Fernandez-Ruiz M, et al. Serum galactomannan versus a combination of galactomannan and polymerase chain reaction-based Aspergillus DNA detection for early therapy of invasive aspergillosis in high-risk hematological patients: a randomized controlled trial. *Clin Infect Dis.* 2015;60(3):405-414.
- Morrissey CO, Chen SC, Sorrell TC, et al. Galactomannan and PCR versus culture and histology for directing use of antifungal treatment for invasive aspergillosis in high-risk haematology patients: a randomised controlled trial. *Lancet Infect Dis.* 2013;13(6):519-528.
- Schneider T, Halter J, Heim D, et al. Pre-emptive diagnosis and treatment of fungal infections—evaluation of a single-centre policy. *Clin Microbiol Infect.* 2012;18(2):189-194.
- Schwarzing M, Sagaon-Teyssier L, Cabaret O, Bretagne S, Cordonnier C. Performance of serum biomarkers for the early detection of invasive aspergillosis in febrile, neutropenic patients: a multi-state model. *PLoS ONE.* 2013;8(6):e65776.
- Aguilar-Guisado M, Martin-Pena A, Espigado I, et al. Universal antifungal therapy is not needed in persistent febrile neutropenia: a tailored diagnostic and therapeutic approach. *Haematologica.* 2012;97(3):464-471.
- Cordonnier C, Pautas C, Maury S, et al. Empirical versus preemptive antifungal therapy for high-risk, febrile, neutropenic patients: a randomized, controlled trial. *Clin Infect Dis.* 2009;48(8):1042-1051.
- Hebart H, Klingspor L, Klingebiel T, et al. A prospective randomized controlled trial comparing PCR-based and empirical treatment with liposomal amphotericin B in patients after allo-SCT. *Bone Marrow Transplant.* 2009;43(7):553-561.
- Tan BH, Low JG, Chlebicka NL, et al. Galactomannan-guided preemptive vs. empirical antifungals in the persistently febrile neutropenic patient: a prospective randomized study. *Int J Infect Dis.* 2011;15(5):e350-e356.
- Maschmeyer G, Heinz WJ, Hertenstein B, et al. Immediate versus deferred empirical antifungal (IDEA) therapy in high-risk patients with febrile neutropenia: a randomized, double-blind, placebo-controlled, multicenter study. *Eur J Clin Microbiol Infect Dis.* 2013;32(5):679-689.
- Cordonnier C, Robin C, Alanio A, Bretagne S. Antifungal pre-emptive strategy for high-risk neutropenic patients: why the story is still ongoing. *Clin Microbiol Infect.* 2014;20(Suppl 6):27-35.



22. Girmenia C, Aversa F, Busca A, et al. A hematology consensus agreement on antifungal strategies for neutropenic patients with hematological malignancies and stem cell transplant recipients. Gruppo Italiano Malattie Ematologiche dell'Adulto, Gruppo Italiano Trapianto di Midollo Osseo, Associazione Italiana Ematologia ed Oncologia Pediatrica, Invasive Fungal Infections Cooperative Group of the European Organization for Research and Treatment of Cancer and Sorveglianza Epidemiologica delle Infezioni Fungine nelle Emopatie Maligne. *Hematol Oncol*. 2013;31(3):117-126.
23. Morrissey CO, Gilroy NM, Macesic N, et al. Consensus guidelines for the use of empiric and diagnostic-driven antifungal treatment strategies in haematological malignancy, 2014. *Intern Med J*. 2014;44(12b):1298-1314.
24. Biehl LM, Vehreschild JJ, Liss B, et al. A cohort study on breakthrough invasive fungal infections in high-risk patients receiving antifungal prophylaxis. *J Antimicrob Chemother*. 2016;71(9):2634-2641.
25. Segal BH. Aspergillosis. *N Engl J Med*. 2009;360(18):1870-1884.
26. Nivoix Y, Velten M, Letscher-Bru V, et al. Factors associated with overall and attributable mortality in invasive aspergillosis. *Clin Infect Dis*. 2008;47(9):1176-1184.
27. Baddley JW, Andes DR, Marr KA, et al. Factors associated with mortality in transplant patients with invasive aspergillosis. *Clin Infect Dis*. 2010;50(12):1559-1567.
28. Pagano L, Caira M, Candoni A, et al. Invasive aspergillosis in patients with acute myeloid leukemia: a SEIFEM-2008 registry study. *Haematologica*. 2010;95(4):644-650.
29. Caillot D, Casasnovas O, Bernard A, et al. Improved management of invasive pulmonary aspergillosis in neutropenic patients using early thoracic computed tomographic scan and surgery. *J Clin Oncol*. 1997;15(1):139-147.
30. Cornely OA, Maertens J, Bresnik M, et al. Liposomal amphotericin B as initial therapy for invasive mold infection: a randomized trial comparing a high-loading dose regimen with standard dosing (AmBiLoad trial). *Clin Infect Dis*. 2007;44(10):1289-1297.
31. Herbrecht R, Denning DW, Patterson TF, et al. Voriconazole versus amphotericin B for primary therapy of invasive aspergillosis. *N Engl J Med*. 2002;347(6):408-415.
32. Maertens JA, Raad II, Marr KA, et al. Isavuconazole versus voriconazole for primary treatment of invasive mould disease caused by Aspergillus and other filamentous fungi (SECURE): a phase 3, randomised-controlled, non-inferiority trial. *Lancet*. 2016;387(10020):760-769.
33. Kontoyiannis DP, Selleslag D, Mullane K, et al. Impact of unresolved neutropenia in patients with neutropenia and invasive aspergillosis: a post hoc analysis of the SECURE trial. *J Antimicrob Chemother*. 2018;73(3):757-763.
34. Maertens J, Selleslag D, Heinz WJ, et al. Treatment outcomes in patients with proven/probable vs possible invasive mould disease in a phase III trial comparing isavuconazole vs voriconazole. *Mycoses*. 2018;61(11):868-876.
35. DiPippo AJ, Rausch CR, Kontoyiannis DP. Tolerability of isavuconazole after posaconazole toxicity in leukaemia patients. *Mycoses*. 2019;62(1):81-86.
36. Boogaerts M, Winston DJ, Bow EJ, et al. Intravenous and oral itraconazole versus intravenous amphotericin B deoxycholate as empirical antifungal therapy for persistent fever in neutropenic patients with cancer who are receiving broad-spectrum antibacterial therapy. A randomized, controlled trial. *Ann Intern Med*. 2001;135(6):412-422.
37. Caillot D, Bassaris H, McGeer A, et al. Intravenous itraconazole followed by oral itraconazole in the treatment of invasive pulmonary aspergillosis in patients with hematologic malignancies, chronic granulomatous disease, or AIDS. *Clin Infect Dis*. 2001;33(8):e83-e90.
38. Denning DW, Lee JY, Hostetler JS, et al. NIAID mycoses study group multicenter trial of oral itraconazole therapy for invasive aspergillosis. *Am J Med*. 1994;97(2):135-144.
39. Glasmacher A, Prentice A. Current experience with itraconazole in neutropenic patients: a concise overview of pharmacological properties and use in prophylactic and empirical antifungal therapy. *Clin Microbiol Infect*. 2006;12(Suppl 7):84-90.
40. Walsh TJ, Raad I, Patterson TF, et al. Treatment of invasive aspergillosis with posaconazole in patients who are refractory to or intolerant of conventional therapy: an externally controlled trial. *Clin Infect Dis*. 2007;44(1):2-12.
41. Cornely OA, Robertson MN, Haider S, et al. Pharmacokinetics and safety results from the Phase 3 randomized, open-label, study of intravenous posaconazole in patients at risk of invasive fungal disease. *J Antimicrob Chemother*. 2017;72(12):3501.
42. Cornely OA, Helfgott D, Langston A, et al. Pharmacokinetics of different dosing strategies of oral posaconazole in patients with compromised gastrointestinal function and who are at high risk for invasive fungal infection. *Antimicrob Agents Chemother*. 2012;56(5):2652-2658.
43. Cornely OA, Duarte RF, Haider S, et al. Phase 3 pharmacokinetics and safety study of a posaconazole tablet formulation in patients at risk for invasive fungal disease. *J Antimicrob Chemother*. 2016;71(6):1747.
44. Gubbins PO, Krishna G, Sansone-Parsons A, et al. Pharmacokinetics and safety of oral posaconazole in neutropenic stem cell transplant recipients. *Antimicrob Agents Chemother*. 2006;50(6):1993-1999.
45. Raad II, Hanna HA, Boktour M, et al. Novel antifungal agents as salvage therapy for invasive aspergillosis in patients with hematologic malignancies: posaconazole compared with high-dose lipid formulations of amphotericin B alone or in combination with caspofungin. *Leukemia*. 2008;22(3):496-503.
46. Raad II, Graybill JR, Bustamante AB, et al. Safety of long-term oral posaconazole use in the treatment of refractory invasive fungal infections. *Clin Infect Dis*. 2006;42(12):1726-1734.
47. Wang EJ, Lew K, Casciano CN, Clement RP, Johnson WW. Interaction of common azole antifungals with P glycoprotein. *Antimicrob Agents Chemother*. 2002;46(1):160-165.
48. van Burik JA, Hare RS, Solomon HF, Corrado ML, Kontoyiannis DP. Posaconazole is effective as salvage therapy in zygomycosis: a retrospective summary of 91 cases. *Clin Infect Dis*. 2006;42(7):e61-e65.
49. Cornely OA, Duarte RF, Haider S, et al. Phase 3 pharmacokinetics and safety study of a posaconazole tablet formulation in patients at risk for invasive fungal disease. *J Antimicrob Chemother*. 2016;71(3):718-726.
50. Bruggemann RJ, Alffenaar JW, Blijlevens NM, et al. Clinical relevance of the pharmacokinetic interactions of azole antifungal drugs with other coadministered agents. *Clin Infect Dis*. 2009;48(10):1441-1458.
51. Groll AH, Townsend R, Desai A, et al. Drug-drug interactions between triazole antifungal agents used to treat invasive aspergillosis and immunosuppressants metabolized by cytochrome P450 3A4. *Transpl Infect Dis*. 2017;19(5):1-11.
52. Patterson TF, Thompson GR III, Denning DW, et al. Practice guidelines for the diagnosis and management of aspergillosis: 2016 update by the infectious diseases society of America. *Clin Infect Dis*. 2016;63(4):e1-e60.
53. Tissot F, Agrawal S, Pagano L, et al. ECIL-6 guidelines for the treatment of invasive candidiasis, aspergillosis and mucormycosis in leukemia and hematopoietic stem cell transplant patients. *Haematologica*. 2017;102(3):433-444.
54. Arendrup MC, Perkhofer S, Howard SJ, et al. Establishing in vitro-in vivo correlations for *Aspergillus fumigatus*: the challenge of azoles versus echinocandins. *Antimicrob Agents Chemother*. 2008;52(10):3504-3511.

55. Lass-Flörl C, Cuenca-Estrella M, Denning DW, Rodríguez-Tudela JL. Antifungal susceptibility testing in *Aspergillus* spp. according to EUCAST methodology. *Med Mycol.* 2006;44(Suppl):319-325.
56. Bellmann R, Smuszkiwicz P. Pharmacokinetics of antifungal drugs: practical implications for optimized treatment of patients. *Infection.* 2017;45(6):737-779.
57. Dolton MJ, Ray JE, Chen SC, Ng K, Pont LG, McLachlan AJ. Multicenter study of voriconazole pharmacokinetics and therapeutic drug monitoring. *Antimicrob Agents Chemother.* 2012;56(9):4793-4799.
58. Schwartz S, Thiel E. Cerebral aspergillosis: tissue penetration is the key. *Med Mycol.* 2009;47(Suppl 1):S387-S393.
59. Andes D, Pascual A, Marchetti O. Antifungal therapeutic drug monitoring: established and emerging indications. *Antimicrob Agents Chemother.* 2009;53(1):24-34.
60. Pascual A, Calandra T, Bolay S, Buclin T, Bille J, Marchetti O. Voriconazole therapeutic drug monitoring in patients with invasive mycoses improves efficacy and safety outcomes. *Clin Infect Dis.* 2008;46(2):201-211.
61. Mitsani D, Nguyen MH, Shields RK, et al. Prospective, observational study of voriconazole therapeutic drug monitoring among lung transplant recipients receiving prophylaxis: factors impacting levels of and associations between serum troughs, efficacy, and toxicity. *Antimicrob Agents Chemother.* 2012;56(5):2371-2377.
62. Pascual A, Csajka C, Buclin T, et al. Challenging recommended oral and intravenous voriconazole doses for improved efficacy and safety: population pharmacokinetics-based analysis of adult patients with invasive fungal infections. *Clin Infect Dis.* 2012;55(3):381-390.
63. Luong ML, Al-Dabbagh M, Groll AH, et al. Utility of voriconazole therapeutic drug monitoring: a meta-analysis. *J Antimicrob Chemother.* 2016;71(7):1786-1799.
64. Dolton MJ, McLachlan AJ. Clinical importance of the CYP2C19\*17 variant allele for voriconazole. *Br J Clin Pharmacol.* 2011;71(1):137-138.
65. Koh H, Hino M, Ohta K, et al. Empirical voriconazole therapy for febrile neutropenic patients with hematological disorders: a prospective multicenter trial in Japan. *J Infect Chemother.* 2013;19(6):1126-1134.
66. Park SY, Yoon JA, Kim SH. Voriconazole-refractory invasive aspergillosis. *Korean J Intern Med.* 2017;32(5):805-812.
67. Viscoli C, Herbrecht R, Akan H, et al. An EORTC Phase II study of caspofungin as first-line therapy of invasive aspergillosis in haematological patients. *J Antimicrob Chemother.* 2009;64(6):1274-1281.
68. Asciglu S, Rex JH, De Pauw B, et al. Defining opportunistic invasive fungal infections in immunocompromised patients with cancer and hematopoietic stem cell transplants: an international consensus. *Clin Infect Dis.* 2002;34(1):7-14.
69. Herbrecht R, Maertens J, Baila L, et al. Caspofungin first-line therapy for invasive aspergillosis in allogeneic hematopoietic stem cell transplant patients: an European Organisation for Research and Treatment of Cancer study. *Bone Marrow Transplant.* 2010;45(7):1227-1233.
70. Maertens J, Egerer G, Shin WS, et al. Caspofungin use in daily clinical practice for treatment of invasive aspergillosis: results of a prospective observational registry. *BMC Infect Dis.* 2010;10:182.
71. Jarque I, Tormo M, Bello JL, et al. Caspofungin for the treatment of invasive fungal disease in hematological patients (ProCAS Study). *Med Mycol.* 2013;51(2):150-154.
72. Cornely OA, Vehreschild JJ, Vehreschild MJ, et al. A phase II dose escalation study of caspofungin for invasive aspergillosis. *Antimicrob Agents Chemother.* 2011;55(12):5798-5803.
73. Betts RF, Nucci M, Talwar D, et al. A Multicenter, double-blind trial of a high-dose caspofungin treatment regimen versus a standard caspofungin treatment regimen for adult patients with invasive candidiasis. *Clin Infect Dis.* 2009;48(12):1676-1684.
74. Cleary JD, Stover KR. Antifungal-associated drug-induced cardiac disease. *Clin Infect Dis.* 2015;61(Suppl 6):S662-S668.
75. Maertens J, Raad I, Petrikos G, et al. Efficacy and safety of caspofungin for treatment of invasive aspergillosis in patients refractory to or intolerant of conventional antifungal therapy. *Clin Infect Dis.* 2004;39(11):1563-1571.
76. Morrissey CO, Slavin MA, O'Reilly MA, et al. Caspofungin as salvage monotherapy for invasive aspergillosis in patients with haematological malignancies or following allogeneic stem cell transplantation: efficacy and concomitant cyclosporin A. *Mycoses.* 2007;50(Suppl 1):24-37.
77. Glasmacher A, Cornely OA, Orlopp K, et al. Caspofungin treatment in severely ill, immunocompromised patients: a case-documentation study of 118 patients. *J Antimicrob Chemother.* 2006;57(1):127-134.
78. Denning DW, Marr KA, Lau WM, et al. Micafungin (FK463), alone or in combination with other systemic antifungal agents, for the treatment of acute invasive aspergillosis. *J Infect.* 2006;53(5):337-349.
79. Kontoyiannis DP, Ratanatharathorn V, Young JA, et al. Micafungin alone or in combination with other systemic antifungal therapies in hematopoietic stem cell transplant recipients with invasive aspergillosis. *Transpl Infect Dis.* 2009;11(1):89-93.
80. Aruanno M, Glampedakis E, Lamoth F. Echinocandins for the treatment of invasive aspergillosis: from laboratory to bedside. *Antimicrob Agents Chemother.* 2019;63(8):e00399-19
81. Ruhnke M, Schwartz S. Recent developments in the management of invasive fungal infections in patients with oncohematological diseases. *Ther Adv Hematol.* 2016;7(6):345-359.
82. Marr KA, Schlamm HT, Herbrecht R, et al. Combination antifungal therapy for invasive aspergillosis: a randomized trial. *Ann Intern Med.* 2015;162(2):81-89.
83. Bowden R, Chandrasekar P, White MH, et al. A double-blind, randomized, controlled trial of amphotericin B colloidal dispersion versus amphotericin B for treatment of invasive aspergillosis in immunocompromised patients. *Clin Infect Dis.* 2002;35(4):359-366.
84. Adler-Moore JP, Gangneux JP, Pappas PG. Comparison between liposomal formulations of amphotericin B. *Med Mycol.* 2016;54(3):223-231.
85. Ringden O, Meunier F, Tollemar J, et al. Efficacy of amphotericin B encapsulated in liposomes (AmBisome) in the treatment of invasive fungal infections in immunocompromised patients. *J Antimicrob Chemother.* 1991;28(Suppl B):73-82.
86. Cordonnier C, Bresnik M, Ebrahimi R. Liposomal amphotericin B (AmBisome) efficacy in confirmed invasive aspergillosis and other filamentous fungal infections in immunocompromised hosts: a pooled analysis. *Mycoses.* 2007;50(3):205-209.
87. Leenders AC, Daenen S, Jansen RL, et al. Liposomal amphotericin B compared with amphotericin B deoxycholate in the treatment of documented and suspected neutropenia-associated invasive fungal infections. *Br J Haematol.* 1998;103(1):205-212.
88. Ostrosky-Zeichner L, Marr KA, Rex JH, Cohen SH. Amphotericin B: time for a new "gold standard". *Clin Infect Dis.* 2003;37(3):415-425.
89. Hachem RY, Boktour MR, Hanna HA, et al. Amphotericin B lipid complex versus liposomal amphotericin B monotherapy for invasive aspergillosis in patients with hematologic malignancy. *Cancer.* 2008;112(6):1282-1287.
90. Ellis M, Spence D, de Pauw B, et al. An EORTC international multicenter randomized trial (EORTC number 19923) comparing two dosages of liposomal amphotericin B for treatment of invasive aspergillosis. *Clin Infect Dis.* 1998;27(6):1406-1412.
91. Wasmann RE, Smit C, van Dongen EPH, et al. Fixed dosing of liposomal amphotericin B in morbidly obese individuals. *Clin Infect Dis.* 2019;ciz885.

92. Ullmann AJ, Sanz MA, Tramarin A, et al. Prospective study of amphotericin B formulations in immunocompromised patients in 4 European countries. *Clin Infect Dis*. 2006;43(4):e29-e38.
93. Gallis HA. Amphotericin B: a commentary on its role as an antifungal agent and as a comparative agent in clinical trials. *Clin Infect Dis*. 1996;22(Suppl 2):S145-S147.
94. Polak A. The past, present and future of antimycotic combination therapy. *Mycoses*. 1999;42(5-6):355-370.
95. Baddley JW, Pappas PG. Combination antifungal therapy for the treatment of invasive yeast and mold infections. *Curr Infect Dis Rep*. 2007;9(6):448-456.
96. Kontoyiannis DP, Lewis RE. Combination chemotherapy for invasive fungal infections: what laboratory and clinical studies tell us so far. *Drug Resist Updat*. 2003;6(5):257-269.
97. Maertens J, Glasmacher A, Herbrecht R, et al. Multicenter, non-comparative study of caspofungin in combination with other antifungals as salvage therapy in adults with invasive aspergillosis. *Cancer*. 2006;107(12):2888-2897.
98. Marr KA, Boeckh M, Carter RA, Kim HW, Corey L. Combination antifungal therapy for invasive aspergillosis. *Clin Infect Dis*. 2004;39(6):797-802.
99. Caillot D, Thiebaut A, Herbrecht R, et al. Liposomal amphotericin B in combination with caspofungin for invasive aspergillosis in patients with hematologic malignancies: a randomized pilot study (Combistrat trial). *Cancer*. 2007;110(12):2740-2746.
100. Segal BH, Herbrecht R, Stevens DA, et al. Defining responses to therapy and study outcomes in clinical trials of invasive fungal diseases: Mycoses Study Group and European Organization for Research and Treatment of Cancer consensus criteria. *Clin Infect Dis*. 2008;47(5):674-683.
101. Caillot D, Couaillier JF, Bernard A, et al. Increasing volume and changing characteristics of invasive pulmonary aspergillosis on sequential thoracic computed tomography scans in patients with neutropenia. *J Clin Oncol*. 2001;19(1):253-259.
102. Maschmeyer G, Haas A. Defining clinical failure for salvage studies. *Med Mycol*. 2006;44(Suppl\_1):S315-S318.
103. Auberger J, Lass-Flörl C, Aigner M, Clausen J, Gastl G, Nachbaur D. Invasive fungal breakthrough infections, fungal colonization and emergence of resistant strains in high-risk patients receiving antifungal prophylaxis with posaconazole: real-life data from a single-centre institutional retrospective observational study. *J Antimicrob Chemother*. 2012;67(9):2268-2273.
104. Hoenigl M, Raggam RB, Salzer HJ, et al. Posaconazole plasma concentrations and invasive mould infections in patients with haematological malignancies. *Int J Antimicrob Agents*. 2012;39(6):510-513.
105. Tverdek FP, Heo ST, Aitken SL, Granwehr B, Kontoyiannis DP. Real-Life assessment of the safety and effectiveness of the new tablet and intravenous formulations of posaconazole in the prophylaxis of invasive fungal infections via analysis of 343 courses. *Antimicrob Agents Chemother*. 2017;61(8):e00188-17.
106. Imhof A, Balajee SA, Fredricks DN, Englund JA, Marr KA. Breakthrough fungal infections in stem cell transplant recipients receiving voriconazole. *Clin Infect Dis*. 2004;39(5):743-746.
107. Kim SB, Cho SY, Lee DG, et al. Breakthrough invasive fungal diseases during voriconazole treatment for aspergillosis: a 5-year retrospective cohort study. *Med Mycol*. 2017;55(3):237-245.
108. Lewis RE, Liao G, Wang W, Prince RA, Kontoyiannis DP. Voriconazole pre-exposure selects for breakthrough mucormycosis in a mixed model of *Aspergillus fumigatus*-*Rhizopus oryzae* pulmonary infection. *Virulence*. 2011;2(4):348-355.
109. Trifilio SM, Bennett CL, Yarnold PR, et al. Breakthrough zygomycosis after voriconazole administration among patients with hematologic malignancies who receive hematopoietic stem-cell transplants or intensive chemotherapy. *Bone Marrow Transplant*. 2007;39(7):425-429.
110. Ceesay MM, Couchman L, Smith M, Wade J, Flanagan RJ, Pagliuca A. Triazole antifungals used for prophylaxis and treatment of invasive fungal disease in adult haematology patients: trough serum concentrations in relation to outcome. *Med Mycol*. 2016;54(7):691-698.
111. Cornely OA, Hoenigl M, Lass-Flörl C, et al. Defining breakthrough invasive fungal infection-Position paper of the mycoses study group education and research consortium and the European Confederation of Medical Mycology. *Mycoses*. 2019;62(9):716-729.
112. Gillespie MB, O'Malley BW. An algorithmic approach to the diagnosis and management of invasive fungal rhinosinusitis in the immunocompromised patient. *Otolaryngol Clin North Am*. 2000;33(2):323-334.
113. Kennedy CA, Adams GL, Neglia JP, Giebink GS. Impact of surgical treatment on paranasal fungal infections in bone marrow transplant patients. *Otolaryngol Head Neck Surg*. 1997;116(6 Pt 1):610-616.
114. Lin SJ, Schranz J, Teutsch SM. Aspergillosis case-fatality rate: systematic review of the literature. *Clin Infect Dis*. 2001;32(3):358-366.
115. Candoni A, Klimko N, Busca A, et al. Fungal infections of the central nervous system and paranasal sinuses in onco-haematologic patients. Epidemiological study reporting the diagnostic-therapeutic approach and outcome in 89 cases. *Mycoses*. 2019;62(3):252-260.
116. Schwartz S, Ruhnke M, Ribaud P, Reed E, Troke P, Thiel E. Poor efficacy of amphotericin B-based therapy in CNS aspergillosis. *Mycoses*. 2007;50(3):196-200.
117. Schwartz S, Ruhnke M, Ribaud P, et al. Improved outcome in central nervous system aspergillosis, using voriconazole treatment. *Blood*. 2005;106(8):2641-2645.
118. Schwartz S, Reisman A, Troke PF. The efficacy of voriconazole in the treatment of 192 fungal central nervous system infections: a retrospective analysis. *Infection*. 2011;39(3):201-210.
119. Schwartz S, Cornely OA, Hamed K, et al. Isavuconazole for the treatment of patients with invasive fungal diseases involving the central nervous system. *Med Mycol*. 2019:1-8. <https://doi.org/10.1093/mmy/myz103> (Online ahead of print).
120. Clemons KV, Espiritu M, Parmar R, Stevens DA. Comparative efficacies of conventional amphotericin b, liposomal amphotericin B (AmBisome), caspofungin, micafungin, and voriconazole alone and in combination against experimental murine central nervous system aspergillosis. *Antimicrob Agents Chemother*. 2005;49(12):4867-4875.
121. Okugawa S, Ota Y, Tatsuno K, Tsukada K, Kishino S, Koike K. A case of invasive central nervous system aspergillosis treated with micafungin with monitoring of micafungin concentrations in the cerebrospinal fluid. *Scand J Infect Dis*. 2007;39(4):344-346.
122. Viscoli C, Girmenia C, Marinus A, et al. Candidemia in cancer patients: a prospective, multicenter surveillance study by the Invasive Fungal Infection Group (IFIG) of the European Organization for Research and Treatment of Cancer (EORTC). *Clin Infect Dis*. 1999;28(5):1071-1079.
123. Cornely OA, Gachot B, Akan H, et al. Epidemiology and outcome of fungemia in a cancer Cohort of the Infectious Diseases Group (IDG) of the European Organization for Research and Treatment of Cancer (EORTC 65031). *Clin Infect Dis*. 2015;61(3):324-331.
124. Pagano L, Dragonetti G, Cattaneo C, et al. Changes in the incidence of candidemia and related mortality in patients with hematologic malignancies in the last ten years. A SEIFEM 2015-B report. *Haematologica*. 2017;102(10):e407-e410.
125. Li D, Xia R, Zhang Q, Bai C, Li Z, Zhang P. Evaluation of candidemia in epidemiology and risk factors among cancer patients in a cancer center of China: an 8-year case-control study. *BMC Infect Dis*. 2017;17(1):536.
126. Morrell M, Fraser VJ, Kollef MH. Delaying the empiric treatment of candida bloodstream infection until positive blood culture

- results are obtained: a potential risk factor for hospital mortality. *Antimicrob Agents Chemother.* 2005;49(9):3640-3645.
127. Mora-Duarte J, Betts R, Rotstein C, et al. Comparison of caspofungin and amphotericin B for invasive candidiasis. *N Engl J Med.* 2002;347(25):2020-2029.
  128. Kuse ER, Chetchotisakd P, da Cunha CA, et al. Micafungin versus liposomal amphotericin B for candidaemia and invasive candidosis: a phase III randomised double-blind trial. *Lancet.* 2007;369(9572):1519-1527.
  129. Wolf HH, Leithauser M, Maschmeyer G, et al. Central venous catheter-related infections in hematology and oncology: guidelines of the Infectious Diseases Working Party (AGIHO) of the German Society of Hematology and Oncology (DGHO). *Ann Hematol.* 2008;87(11):863-876.
  130. Anaissie EJ, Darouiche RO, Abi-Said D, et al. Management of invasive candidal infections: results of a prospective, randomized, multicenter study of fluconazole versus amphotericin B and review of the literature. *Clin Infect Dis.* 1996;23(5):964-972.
  131. Anaissie EJ, Vartivarian SE, Abi-Said D, et al. Fluconazole versus amphotericin B in the treatment of hematogenous candidiasis: a matched cohort study. *Am J Med.* 1996;101(2):170-176.
  132. Perfect JR, Marr KA, Walsh TJ, et al. Voriconazole treatment for less-common, emerging, or refractory fungal infections. *Clin Infect Dis.* 2003;36(9):1122-1131.
  133. Kullberg BJ, Sobel JD, Ruhnke M, et al. Voriconazole versus a regimen of amphotericin B followed by fluconazole for candidaemia in non-neutropenic patients: a randomised non-inferiority trial. *Lancet.* 2005;366(9495):1435-1442.
  134. Kullberg BJ, Viscoli C, Pappas PG, et al. Isavuconazole versus caspofungin in the treatment of candidemia and other invasive candida infections: the ACTIVE trial. *Clin Infect Dis.* 2019;68(12):1981-1989.
  135. Bates DW, Su L, Yu DT, et al. Mortality and costs of acute renal failure associated with amphotericin B therapy. *Clin Infect Dis.* 2001;32(5):686-693.
  136. Harbarth S, Burke JP, Lloyd JF, Evans RS, Pestotnik SL, Samore MH. Clinical and economic outcomes of conventional amphotericin B-associated nephrotoxicity. *Clin Infect Dis.* 2002;35(12):e120-e127.
  137. Chandrasekar P, Sirohi B, Seibel NL, et al. Efficacy of micafungin for the treatment of invasive candidiasis and candidaemia in patients with neutropenia. *Mycoses.* 2018;61(5):331-336.
  138. Kimura M, Araoka H, Yamamoto H, et al. Clinical and microbiological characteristics of breakthrough candidemia in allogeneic hematopoietic stem cell transplant recipients in a Japanese hospital. *Antimicrob Agents Chemother.* 2017;61(4):e01791-e1816.
  139. Reboli AC, Rotstein C, Pappas PG, et al. Anidulafungin versus fluconazole for invasive candidiasis. *N Engl J Med.* 2007;356(24):2472-2482.
  140. Pappas PG, Rotstein CM, Betts RF, et al. Micafungin versus caspofungin for treatment of candidemia and other forms of invasive candidiasis. *Clin Infect Dis.* 2007;45(7):883-893.
  141. Cornely OA, Lasso M, Betts R, et al. Caspofungin for the treatment of less common forms of invasive candidiasis. *J Antimicrob Chemother.* 2007;60(2):363-369.
  142. Cornely OA, Vazquez J, De WJ, et al. Efficacy of micafungin in invasive candidiasis caused by common *Candida* species with special emphasis on non-albicans *Candida* species. *Mycoses.* 2014;57(2):79-89.
  143. Rex JH, Pappas PG, Karchmer AW, et al. A randomized and blinded multicenter trial of high-dose fluconazole plus placebo versus fluconazole plus amphotericin B as therapy for candidemia and its consequences in nonneutropenic subjects. *Clin Infect Dis.* 2003;36(10):1221-1228.
  144. Lehrnbecher T, Kaiser J, Varwig D, et al. Antifungal usage in children undergoing intensive treatment for acute myeloid leukemia: analysis of the multicenter clinical trial AML-BFM 93. *Eur J Clin Microbiol Infect Dis.* 2007;26(10):735-738.
  145. Hope WW, Warn PA, Sharp A, et al. Optimization of the dosage of flucytosine in combination with amphotericin B for disseminated candidiasis: a pharmacodynamic rationale for reduced dosing. *Antimicrob Agents Chemother.* 2007;51(10):3760-3762.
  146. Abele-Horn M, Kopp A, Sternberg U, et al. A randomized study comparing fluconazole with amphotericin B/5-flucytosine for the treatment of systemic *Candida* infections in intensive care patients. *Infection.* 1996;24(6):426-432.
  147. Francis P, Walsh TJ. Evolving role of flucytosine in immunocompromised patients: new insights into safety, pharmacokinetics, and antifungal therapy. *Clin Infect Dis.* 1992;15(6):1003-1018.
  148. Ruhnke M, Rickerts V, Cornely OA, et al. Diagnosis and therapy of *Candida* infections: joint recommendations of the German Speaking Mycological Society and the Paul-Ehrlich-Society for Chemotherapy. *Mycoses.* 2011;54(4):279-310.
  149. Guarana M, Nucci M. Acute disseminated candidiasis with skin lesions: a systematic review. *Clin Microbiol Infect.* 2018;24(3):246-250.
  150. Anaissie E, Pinczowski H. Invasive candidiasis during granulocytopenia. *Recent Results Cancer Res.* 1993;132:137-145.
  151. Slavin MA, Sorrell TC, Marriott D, et al. Candidaemia in adult cancer patients: risks for fluconazole-resistant isolates and death. *J Antimicrob Chemother.* 2010;65(5):1042-1051.
  152. Wenzel RP, Gennings C. Bloodstream infections due to *Candida* species in the intensive care unit: identifying especially high-risk patients to determine prevention strategies. *Clin Infect Dis.* 2005;41(Suppl 6):S389-S393.
  153. Andes DR, Safdar N, Baddley JW, et al. Impact of treatment strategy on outcomes in patients with candidemia and other forms of invasive candidiasis: a patient-level quantitative review of randomized trials. *Clin Infect Dis.* 2012;54(8):1110-1122.
  154. Raad I, Hanna H, Boktour M, et al. Management of central venous catheters in patients with cancer and candidemia. *Clin Infect Dis.* 2004;38(8):1119-1127.
  155. Nucci M, Anaissie E, Betts RF, et al. Early removal of central venous catheter in patients with candidemia does not improve outcome: analysis of 842 patients from 2 randomized clinical trials. *Clin Infect Dis.* 2010;51(3):295-303.
  156. Hentrich M, Schalk E, Schmidt-Hieber M, et al. Central venous catheter-related infections in hematology and oncology: 2012 updated guidelines on diagnosis, management and prevention by the Infectious Diseases Working Party of the German Society of Hematology and Medical Oncology. *Ann Oncol.* 2014;25(5):936-947.
  157. Tang HJ, Liu WL, Lin HL, Lai CC. Epidemiology and prognostic factors of candidemia in elderly patients. *Geriatr Gerontol Int.* 2015;15(6):688-693.
  158. Nucci M, Anaissie E. Should vascular catheters be removed from all patients with candidemia? An evidence-based review. *Clin Infect Dis.* 2002;34(5):591-599.
  159. Kuhn DM, George T, Chandra J, Mukherjee PK, Ghannoum MA. Antifungal susceptibility of *Candida* biofilms: unique efficacy of amphotericin B lipid formulations and echinocandins. *Antimicrob Agents Chemother.* 2002;46(6):1773-1780.
  160. van Prehn J, Menke-van der Houven van Oordt CW, de Rooij ML, Meijer E, Bomers K, van Dijk K. Hepatosplenic candidiasis without prior documented candidemia: an underrecognized diagnosis? *Oncologist.* 2017;22(8):989-994.
  161. Walsh TJ, Whitcomb PO, Revankar SG, Pizzo PA. Successful treatment of hepatosplenic candidiasis through repeated cycles of chemotherapy and neutropenia. *Cancer.* 1995;76(11):2357-2362.
  162. Karthaus M, Hebart H, Einsele H, et al. Long-term survival in patients with acute leukemia and chronic disseminated candidiasis despite minimal antileukemic therapy. *Haematologica.* 2006;91(10):1422-1423.



163. Poon LM, Chia HY, Tan LK, Liu TC, Koh LP. Successful intensive chemotherapy followed by autologous hematopoietic cell transplantation in a patient with acute myeloid leukemia and hepatosplenic candidiasis: case report and review of literature. *Transpl Infect Dis.* 2009;11(2):160-166.
164. Walsh TJ, Whitcomb P, Piscitelli S, et al. Safety, tolerance, and pharmacokinetics of amphotericin B lipid complex in children with hepatosplenic candidiasis. *Antimicrob Agents Chemother.* 1997;41(9):1944-1948.
165. Kauffman CA, Bradley SF, Ross SC, Weber DR. Hepatosplenic candidiasis: successful treatment with fluconazole. *Am J Med.* 1991;91(2):137-141.
166. Arda B, Soyer N, Sipahi OR, et al. Possible hepatosplenic candidiasis treated with liposomal amphotericin B and caspofungin combination. *J Infect.* 2006;52(5):387-388.
167. Rammaert B, Desjardins A, Lortholary O. New insights into hepatosplenic candidosis, a manifestation of chronic disseminated candidosis. *Mycoses.* 2012;55(3):e74-e84.
168. Legrand F, Lecuit M, Dupont B, et al. Adjuvant corticosteroid therapy for chronic disseminated candidiasis. *Clin Infect Dis.* 2008;46(5):696-702.
169. Vazquez J, Reboli AC, Pappas PG, et al. Evaluation of an early step-down strategy from intravenous anidulafungin to oral azole therapy for the treatment of candidemia and other forms of invasive candidiasis: results from an open-label trial. *BMC Infect Dis.* 2014;14:97.
170. Schwartz S, Kontoyiannis DP, Harrison T, Ruhnke M. Advances in the diagnosis and treatment of fungal infections of the CNS. *Lancet Neurol.* 2018;17(4):362-372.
171. O'Brien D, Stevens NT, Lim CH, et al. Candida infection of the central nervous system following neurosurgery: a 12-year review. *Acta Neurochir (Wien).* 2011;153(6):1347-1350.
172. Gavino C, Cotter A, Lichtenstein D, et al. CARD9 deficiency and spontaneous central nervous system candidiasis: complete clinical remission with GM-CSF therapy. *Clin Infect Dis.* 2014;59(1):81-84.
173. Liu KH, Wu CJ, Chou CH, et al. Refractory candidal meningitis in an immunocompromised patient cured by caspofungin. *J Clin Microbiol.* 2004;42(12):5950-5953.
174. Kang CI, Rouse MS, Mandrekar JN, Steckelberg JM, Patel R. Anidulafungin treatment of candidal central nervous system infection in a murine model. *Antimicrob Agents Chemother.* 2009;53(8):3576-3578.
175. Auriti C, Falcone M, Ronchetti MP, et al. High-dose micafungin for preterm neonates and infants with invasive and central nervous system candidiasis. *Antimicrob Agents Chemother.* 2016;60(12):7333-7339.
176. Sobel JD, Fisher JF, Kauffman CA, Newman CA. Candida urinary tract infections—epidemiology. *Clin Infect Dis.* 2011;52(Suppl 6):S433-S436.
177. Sobel JD, Kauffman CA, McKinsey D, et al. Candiduria: a randomized, double-blind study of treatment with fluconazole and placebo. The National Institute of Allergy and Infectious Diseases (NIAID) Mycoses Study Group. *Clin Infect Dis.* 2000;30(1):19-24.
178. Georgiadou SP, Tarrand J, Sipsas NV, Kontoyiannis DP. Candiduria in haematologic malignancy patients without a urinary catheter: nothing more than a frailty marker? *Mycoses.* 2013;56(3):311-314.
179. Kontoyiannis DP, Azie N, Franks B, Horn DL. Prospective antifungal therapy (PATH) alliance®: focus on mucormycosis. *Mycoses.* 2014;57(4):240-246.
180. Horger M, Einsele H, Schumacher U, et al. Invasive pulmonary aspergillosis: frequency and meaning of the "hypodense sign" on unenhanced CT. *Br J Radiol.* 2005;78(932):697-703.
181. Nucci M, Nouer SA, Graziutti M, Kumar NS, Barlogie B, Anaissie E. Probable invasive aspergillosis without prespecified radiologic findings: proposal for inclusion of a new category of aspergillosis and implications for studying novel therapies. *Clin Infect Dis.* 2010;51(11):1273-1280.
182. Godoy MC, Viswanathan C, Marchiori E, et al. The reversed halo sign: update and differential diagnosis. *Br J Radiol.* 2012;85(1017):1226-1235.
183. Marchiori E, Hochhegger B, Zanetti G. Reversed halo sign in invasive fungal infections. *J Bras Pneumol.* 2016;42(3):232.
184. Busca A, Limerutti G, Locatelli F, Barbui A, De Rosa FG, Falda M. The reversed halo sign as the initial radiographic sign of pulmonary zygomycosis. *Infection.* 2012;40(1):77-80.
185. Lass-Flörl C, Aigner M, Nachbaur D, et al. Diagnosing filamentous fungal infections in immunocompromised patients applying computed tomography-guided percutaneous lung biopsies: a 12-year experience. *Infection.* 2017;45(6):867-875.
186. Skiada A, Lanternier F, Groll AH, et al. Diagnosis and treatment of mucormycosis in patients with hematological malignancies: guidelines from the 3rd European Conference on Infections in Leukemia (ECIL 3). *Haematologica.* 2013;98(4):492-504.
187. Marty FM, Ostrosky-Zeichner L, Cornely OA, et al. Isavuconazole treatment for mucormycosis: a single-arm open-label trial and case-control analysis. *Lancet Infect Dis.* 2016;16(7):828-837.
188. Roden MM, Zaoutis TE, Buchanan WL, et al. Epidemiology and outcome of zygomycosis: a review of 929 reported cases. *Clin Infect Dis.* 2005;41(5):634-653.
189. Perfect JR. Treatment of non-Aspergillus moulds in immunocompromised patients, with amphotericin B lipid complex. *Clin Infect Dis.* 2005;40(Suppl 6):S401-S408.
190. Shoham S, Magill SS, Merz WG, et al. Primary treatment of zygomycosis with liposomal amphotericin B: analysis of 28 cases. *Med Mycol.* 2010;48(3):511-517.
191. Rüping MJ, Heinz WJ, Kindo AJ, et al. Forty-one recent cases of invasive zygomycosis from a global clinical registry. *J Antimicrob Chemother.* 2010;65(2):296-302.
192. Riley TT, Muzny CA, Swiatlo E, Legendre DP. Breaking the mold: a review of mucormycosis and current pharmacological treatment options. *Ann Pharmacother.* 2016;50(9):747-757.
193. Lanternier F, Poiree S, Elie C, et al. Prospective pilot study of high-dose (10 mg/kg/day) liposomal amphotericin B (L-AMB) for the initial treatment of mucormycosis. *J Antimicrob Chemother.* 2015;70(11):3116-3123.
194. Vehreschild JJ, Birtel A, Vehreschild MJ, et al. Mucormycosis treated with posaconazole: review of 96 case reports. *Crit Rev Microbiol.* 2013;39(3):310-324.
195. Greenberg RN, Mullane K, van Burik JA, et al. Posaconazole as salvage therapy for zygomycosis. *Antimicrob Agents Chemother.* 2006;50(1):126-133.
196. Segal BH, Barnhart LA, Anderson VL, Walsh TJ, Malech HL, Holland SM. Posaconazole as salvage therapy in patients with chronic granulomatous disease and invasive filamentous fungal infection. *Clin Infect Dis.* 2005;40(11):1684-1688.
197. Pagano L, Cornely OA, Busca A, et al. Combined antifungal approach for the treatment of invasive mucormycosis in patients with hematologic diseases: a report from the SEIFEM and FUNGISCOPE registries. *Haematologica.* 2013;98(10):e127-e130.
198. Reed C, Bryant R, Ibrahim AS, et al. Combination polyene-caspofungin treatment of rhino-orbital-cerebral mucormycosis. *Clin Infect Dis.* 2008;47(3):364-371.
199. Gebremariam T, Wiederhold NP, Alqarihi A, et al. Monotherapy or combination therapy of isavuconazole and micafungin for treating murine mucormycosis. *J Antimicrob Chemother.* 2017;72(2):462-466.

200. Walsh TJ, Hiemenz JW, Seibel NL, et al. Amphotericin B lipid complex for invasive fungal infections: analysis of safety and efficacy in 556 cases. *Clin Infect Dis*. 1998;26(6):1383-1396.
201. Pagano L, Offidani M, Fianchi L, et al. Mucormycosis in hematologic patients. *Haematologica*. 2004;89(2):207-214.
202. Herbrecht R, Letscher-Bru V, Bowden RA, et al. Treatment of 21 cases of invasive mucormycosis with amphotericin B colloidal dispersion. *Eur J Clin Microbiol Infect Dis*. 2001;20(7):460-466.
203. Kobayashi K, Kami M, Murashige N, Kishi Y, Fujisaki G, Mitamura T. Breakthrough zygomycosis during voriconazole treatment for invasive aspergillosis. *Haematologica*. 2004;89(11):ECR42.
204. Marty FM, Cosimi LA, Baden LR. Breakthrough zygomycosis after voriconazole treatment in recipients of hematopoietic stem-cell transplants. *N Engl J Med*. 2004;350(9):950-952.
205. Oren I. Breakthrough zygomycosis during empirical voriconazole therapy in febrile patients with neutropenia. *Clin Infect Dis*. 2005;40(5):770-771.
206. Schalk E, Mohren M, Jentsch-Ullrich K, Dombrowski F, Franke A, Koenigsmann M. Zygomycoses in patients with acute leukaemia. *Ann Hematol*. 2006;85(5):327-332.
207. Wingard JR, Carter SL, Walsh TJ, et al. Randomized, double-blind trial of fluconazole versus voriconazole for prevention of invasive fungal infection after allogeneic hematopoietic cell transplantation. *Blood*. 2010;116(24):5111-5118.
208. Rosillo C, Avila AM, Huang YT, et al. Sequential systematic anti-mold prophylaxis with micafungin and voriconazole results in very low incidence of invasive mold infections in patients undergoing allogeneic hematopoietic stem cell transplantation. *Transpl Infect Dis*. 2018;20(4):e12897.
209. Marks DI, Pagliuca A, Kibbler CC, et al. Voriconazole versus itraconazole for antifungal prophylaxis following allogeneic haematopoietic stem-cell transplantation. *Br J Haematol*. 2011;155(3):318-327.
210. Williamson PR, Jarvis JN, Panackal AA, et al. Cryptococcal meningitis: epidemiology, immunology, diagnosis and therapy. *Nat Rev Neurol*. 2017;13(1):13-24.
211. Wang RY, Chen YQ, Wu JQ, et al. Cryptococcosis in patients with hematological diseases: a 14-year retrospective clinical analysis in a Chinese tertiary hospital. *BMC Infect Dis*. 2017;17(1):463.
212. Zonios DI, Falloon J, Huang CY, Chaitt D, Bennett JE. Cryptococcosis and idiopathic CD4 lymphocytopenia. *Medicine (Baltimore)*. 2007;86(2):78-92.
213. Schmalzle SA, Buchwald UK, Gilliam BL, Riedel DJ. Cryptococcus neoformans infection in malignancy. *Mycoses*. 2016;59(9):542-552.
214. McMullan BJ, Sorrell TC, Chen SC. Cryptococcus gattii infections: contemporary aspects of epidemiology, clinical manifestations and management of infection. *Future Microbiol*. 2013;8(12):1613-1631.
215. Perfect JR, Dismukes WE, Dromer F, et al. Clinical practice guidelines for the management of cryptococcal disease: 2010 update by the infectious diseases society of america. *Clin Infect Dis*. 2010;50(3):291-322.
216. Patel RKK, Leeme T, Azzo C, et al. High mortality in HIV-associated cryptococcal meningitis patients treated with amphotericin B-based therapy under routine care conditions in Africa. *Open Forum Infect Dis*. 2018;5(11):ofy267.
217. Schmidt-Hieber M, Silling G, Schalk E, et al. CNS infections in patients with hematological disorders (including allogeneic stem-cell transplantation)-Guidelines of the Infectious Diseases Working Party (AGIHO) of the German Society of Hematology and Medical Oncology (DGHO). *Ann Oncol*. 2016;27(7):1207-1225.
218. Hamill RJ, Sobel JD, el-Sadr W, et al. Comparison of 2 doses of liposomal amphotericin B and conventional amphotericin B deoxycholate for treatment of AIDS-associated acute cryptococcal meningitis: a randomized, double-blind clinical trial of efficacy and safety. *Clin Infect Dis*. 2010;51(2):225-232.
219. Tenforde MW, Shapiro AE, Rouse B, et al. Treatment for HIV-associated cryptococcal meningitis. *Cochrane Database Syst Rev*. 2018;7:CD005647.
220. Day JN, Chau TT, Wolbers M, et al. Combination antifungal therapy for cryptococcal meningitis. *N Engl J Med*. 2013;368(14):1291-1302.
221. Chen SC, Sorrell TC, Chang CC, Paige EK, Bryant PA, Slavin MA. Consensus guidelines for the treatment of yeast infections in the haematology, oncology and intensive care setting, 2014. *Intern Med J*. 2014;44(12b):1315-1332.
222. Bicanic T, Bottomley C, Loyse A, et al. Toxicity of amphotericin B deoxycholate-based induction therapy in patients with HIV-associated cryptococcal meningitis. *Antimicrob Agents Chemother*. 2015;59(12):7224-7231.
223. Molloy SF, Kanyama C, Heyderman RS, et al. Antifungal combinations for treatment of cryptococcal meningitis in Africa. *N Engl J Med*. 2018;378(11):1004-1017.
224. Loyse A, Wilson D, Meintjes G, et al. Comparison of the early fungicidal activity of high-dose fluconazole, voriconazole, and flucytosine as second-line drugs given in combination with amphotericin B for the treatment of HIV-associated cryptococcal meningitis. *Clin Infect Dis*. 2012;54(1):121-128.
225. Concha-Velasco F, Gonzalez-Lagos E, Seas C, Bustamante B. Factors associated with early mycological clearance in HIV-associated cryptococcal meningitis. *PLoS ONE*. 2017;12(3):e0174459.
226. Gamaletsou MN, Sipsas NV, Kontoyiannis DP, et al. Successful salvage therapy of refractory HIV-related cryptococcal meningitis with the combination of liposomal amphotericin B, voriconazole, and recombinant interferon-gamma. *Diagn Microbiol Infect Dis*. 2012;74(4):409-411.
227. Lawrence DS, Youssouf N, Molloy SF, et al. AMBIsome Therapy Induction Optimisation (AMBITION): high dose am bisome for cryptococcal meningitis induction therapy in sub-Saharan Africa: study protocol for a phase 3 randomised controlled non-inferiority trial. *Trials*. 2018;19(1):649.
228. Flores VG, Tovar RM, Zaldivar PG, Martinez EA. Meningitis due to Cryptococcus neoformans: treatment with posaconazole. *Curr HIV Res*. 2012;10(7):620-623.
229. Pitisuttithum P, Negroni R, Graybill JR, et al. Activity of posaconazole in the treatment of central nervous system fungal infections. *J Antimicrob Chemother*. 2005;56(4):745-755.
230. Yao ZW, Lu X, Shen C, Lin DF. Comparison of flucytosine and fluconazole combined with amphotericin B for the treatment of HIV-associated cryptococcal meningitis: a systematic review and meta-analysis. *Eur J Clin Microbiol Infect Dis*. 2014;33(8):1339-1344.
231. Thompson GR III, Rendon A, Dos Ribeiro SR, et al. Isavuconazole treatment of cryptococcosis and dimorphic mycoses. *Clin Infect Dis*. 2016;63(3):356-362.
232. Jarvis JN, Leeme TB, Molefi M, et al. Short-course high-dose liposomal amphotericin B for human immunodeficiency virus-associated cryptococcal meningitis: a phase 2 randomized controlled trial. *Clin Infect Dis*. 2019;68(3):393-401.
233. Bicanic T, Harrison T, Niepieklo A, Dyakopu N, Meintjes G. Symptomatic relapse of HIV-associated cryptococcal meningitis after initial fluconazole monotherapy: the role of fluconazole resistance and immune reconstitution. *Clin Infect Dis*. 2006;43(8):1069-1073.
234. Pfaller MA, Rhomberg PR, Messer SA, Jones RN, Castanheira M. Isavuconazole, micafungin, and 8 comparator antifungal agents' susceptibility profiles for common and uncommon opportunistic fungi collected in 2013: temporal analysis of antifungal drug resistance using CLSI species-specific clinical breakpoints and proposed epidemiological cutoff values. *Diagn Microbiol Infect Dis*. 2015;82(4):303-313.



235. Lee WS, Hsieh TC, Ou TY, Teng SO, Chen FL, Wang FD. Breakthrough disseminated cryptococcosis during micafungin therapy. *J Microbiol Immunol Infect.* 2015;48(4):456-458.
236. Horn DL, Freifeld AG, Schuster MG, Azie NE, Franks B, Kauffman CA. Treatment and outcomes of invasive fusariosis: review of 65 cases from the PATH Alliance® registry. *Mycoses.* 2014;57(11):652-658.
237. Garcia-Ruiz JC, Olazabal I, den Pedroso RM, et al. Disseminated fusariosis and hematologic malignancies, a still devastating association. Report of three new cases. *Rev Iberoam Micol.* 2015;32(3):190-196.
238. Campo M, Lewis RE, Kontoyiannis DP. Invasive fusariosis in patients with hematologic malignancies at a cancer center: 1998–2009. *J Infect.* 2010;60(5):331-337.
239. Nucci M, Garnica M, Gloria AB, et al. Invasive fungal diseases in haematopoietic cell transplant recipients and in patients with acute myeloid leukaemia or myelodysplasia in Brazil. *Clin Microbiol Infect.* 2013;19(8):745-751.
240. Kontoyiannis DP, Bodey GP, Hanna H, et al. Outcome determinants of fusariosis in a tertiary care cancer center: the impact of neutrophil recovery. *Leuk Lymphoma.* 2004;45(1):139-141.
241. McCarthy MW, Katragkou A, Iosifidis E, Roilides E, Walsh TJ. Recent advances in the treatment of scedosporiosis and fusariosis. *J Fungi (Basel).* 2018;4(2):E73.
242. Yu J, Chen Y, Fang J, Zhang K. Successful treatment of disseminated fusariosis in a patient with acute lymphoblastic leukemia: A case report and literature review. *Medicine (Baltimore).* 2019;98(26):e16246.
243. Muhammed M, Anagnostou T, Desalermos A, et al. Fusarium infection: report of 26 cases and review of 97 cases from the literature. *Medicine (Baltimore).* 2013;92(6):305-316.
244. Lortholary O, Obenga G, Biswas P, et al. International retrospective analysis of 73 cases of invasive fusariosis treated with voriconazole. *Antimicrob Agents Chemother.* 2010;54(10):4446-4450.
245. Nucci M, Marr KA, Vehreschild MJ, et al. Improvement in the outcome of invasive fusariosis in the last decade. *Clin Microbiol Infect.* 2014;20(6):580-585.
246. Liu JY, Chen WT, Ko BS, et al. Combination antifungal therapy for disseminated fusariosis in immunocompromised patients: a case report and literature review. *Med Mycol.* 2011;49(8):872-878.
247. Tortorano AM, Richardson M, Roilides E, et al. ESCMID and ECMM joint guidelines on diagnosis and management of hyalohyphomycosis: *Fusarium* spp., *Scedosporium* spp. and others. *Clin Microbiol Infect.* 2014;20(Suppl 3):27-46.
248. Wu CH, Lu PL, Hsiao HH, et al. Breakthrough *Fusarium solani* infection in a patient with acute myeloid leukemia receiving posaconazole prophylaxis. *Ann Hematol.* 2014;93(6):1079-1081.
249. Kadri SS, Remy KE, Strich JR, Gea-Banacloche J, Leitman SF. Role of granulocyte transfusions in invasive fusariosis: systematic review and single-center experience. *Transfusion.* 2015;55(9):2076-2085.
250. Stempel JM, Hammond SP, Sutton DA, Weiser LM, Marty FM. Invasive fusariosis in the voriconazole era: single-center 13-year experience. *Open Forum Infect Dis.* 2015;2(3):ofv099.
251. de Hoog GS, Chaturvedi V, Denning DW, et al. Name changes in medically important fungi and their implications for clinical practice. *J Clin Microbiol.* 2015;53(4):1056-1062.
252. Colombo AL, Padovan AC, Chaves GM. Current knowledge of *Trichosporon* spp. and *Trichosporonosis*. *Clin Microbiol Rev.* 2011;24(4):682-700.
253. Girmenia C, Pagano L, Martino B, et al. Invasive infections caused by *Trichosporon* species and *Geotrichum capitatum* in patients with hematological malignancies: a retrospective multicenter study from Italy and review of the literature. *J Clin Microbiol.* 2005;43(4):1818-1828.
254. Fernandez-Ruiz M, Guinea J, Puig-Asensio M, et al. Fungemia due to rare opportunistic yeasts: data from a population-based surveillance in Spain. *Med Mycol.* 2017;55(2):125-136.
255. de Almeida Junior JN, Hennequin C. Invasive trichosporon infection: a systematic review on a re-emerging fungal pathogen. *Front Microbiol.* 2016;7:1629.
256. Kontoyiannis DP, Torres HA, Chagua M, et al. Trichosporonosis in a tertiary care cancer center: risk factors, changing spectrum and determinants of outcome. *Scand J Infect Dis.* 2004;36(8):564-569.
257. Alby-Laurent F, Dollfus C, it-Oufella H, et al. Trichosporon: another yeast-like organism responsible for immune reconstitution inflammatory syndrome in patients with hematological malignancy. *Hematol Oncol.* 2017;35(4):900-904.
258. Matsue K, Uryu H, Koseki M, Asada N, Takeuchi M. Breakthrough trichosporonosis in patients with hematologic malignancies receiving micafungin. *Clin Infect Dis.* 2006;42(6):753-757.
259. Foster CE, Edwards MS, Brackett J, Schady DA, Healy CM, Baker CJ. Trichosporonosis in pediatric patients with a hematologic disorder. *J Pediatric Infect Dis Soc.* 2018;7(3):199-204.
260. Krcmery V Jr, Mateicka F, Kunova A, et al. Hematogenous trichosporonosis in cancer patients: report of 12 cases including 5 during prophylaxis with itraconazole. *Support Care Cancer.* 1999;7(1):39-43.
261. Rieger C, Geiger S, Herold T, Nickenig C, Ostermann H. Breakthrough infection of *Trichosporon asahii* during posaconazole treatment in a patient with acute myeloid leukaemia. *Eur J Clin Microbiol Infect Dis.* 2007;26(11):843-845.
262. Suzuki K, Nakase K, Kyo T, et al. Fatal *Trichosporon* fungemia in patients with hematologic malignancies. *Eur J Haematol.* 2010;84(5):441-447.
263. Ruan SY, Chien JY, Hsueh PR. Invasive trichosporonosis caused by *Trichosporon asahii* and other unusual *Trichosporon* species at a medical center in Taiwan. *Clin Infect Dis.* 2009;49(1):e11-e17.
264. Fournier S, Pavageau W, Feuillhade M, et al. Use of voriconazole to successfully treat disseminated *Trichosporon asahii* infection in a patient with acute myeloid leukaemia. *Eur J Clin Microbiol Infect Dis.* 2002;21(12):892-896.
265. Asada N, Uryu H, Koseki M, Takeuchi M, Komatsu M, Matsue K. Successful treatment of breakthrough *Trichosporon asahii* fungemia with voriconazole in a patient with acute myeloid leukemia. *Clin Infect Dis.* 2006;43(4):e39-e41.
266. Thien SY, Chung SJ, Tan AL, Hwang WY, Tan BH, Tan TT. Recurrent trichosporonosis with central nervous system involvement in an allogeneic hematopoietic stem cell transplant recipient. *Transpl Infect Dis.* 2016;18(5):768-772.
267. Karigane D, Sakurai M, Matsuyama E, et al. Successful treatment of breakthrough disseminated *Trichosporon asahii* fungemia in a patient with acute myeloid leukemia receiving itraconazole prophylaxis. *Med Mycol Case Rep.* 2018;20:1-3.
268. Falk R, Wolf DG, Shapiro M, Polacheck I. Multidrug-resistant *Trichosporon asahii* isolates are susceptible to voriconazole. *J Clin Microbiol.* 2003;41(2):911.
269. Dos Santos CO, Zijlstra JG, Porte RJ, et al. Emerging pan-resistance in *Trichosporon* species: a case report. *BMC Infect Dis.* 2016;16:148.
270. Hosokawa K, Yamazaki H, Mochizuki K, et al. Successful treatment of *Trichosporon* fungemia in a patient with refractory acute myeloid leukemia using voriconazole combined with liposomal amphotericin B. *Transpl Infect Dis.* 2012;14(2):184-187.
271. Bassetti M, Bisio F, Di BA, et al. *Trichosporon asahii* infection treated with caspofungin combined with liposomal amphotericin B. *J Antimicrob Chemother.* 2004;54(2):575-577.
272. Arendrup MC, Boekhout T, Akova M, Meis JF, Cornely OA, Lortholary O. ESCMID and ECMM joint clinical guidelines for the diagnosis and management of rare invasive yeast infections. *Clin Microbiol Infect.* 2014;20(Suppl 3):76-98.

273. Ramirez-Garcia A, Pellon A, Rementeria A, et al. Scedosporium and Lomentospora: an updated overview of underrated opportunists. *Med Mycol.* 2018;56(suppl\_1):102-125.
274. Tamaki M, Nozaki K, Onishi M, Yamamoto K, Ujiie H, Sugahara H. Fungal meningitis caused by Lomentospora prolificans after allogeneic hematopoietic stem cell transplantation. *Transpl Infect Dis.* 2016;18(4):601-605.
275. Rodriguez-Tudela JL, Berenguer J, Guarro J, et al. Epidemiology and outcome of Scedosporium prolificans infection, a review of 162 cases. *Med Mycol.* 2009;47(4):359-370.
276. Tintelnot K, Just-Nubling G, Horre R, et al. A review of German Scedosporium prolificans cases from 1993 to 2007. *Med Mycol.* 2009;47(4):351-358.
277. Lamaris GA, Chamilos G, Lewis RE, Safdar A, Raad II, Kontoyiannis DP. Scedosporium infection in a tertiary care cancer center: a review of 25 cases from 1989-2006. *Clin Infect Dis.* 2006;43(12):1580-1584.
278. Cortez KJ, Roilides E, Quiroz-Telles F, et al. Infections caused by Scedosporium spp. *Clin Microbiol Rev.* 2008;21(1):157-197.
279. Wiederhold NP, Lewis RE. Antifungal activity against Scedosporium species and novel assays to assess antifungal pharmacodynamics against filamentous fungi. *Med Mycol.* 2009;47(4):422-432.
280. Cuenca-Estrella M, Gomez-Lopez A, Mellado E, Buitrago MJ, Monzon A, Rodriguez-Tudela JL. Head-to-head comparison of the activities of currently available antifungal agents against 3,378 Spanish clinical isolates of yeasts and filamentous fungi. *Antimicrob Agents Chemother.* 2006;50(3):917-921.
281. Seidel D, Meissner A, Lackner M, et al. Prognostic factors in 264 adults with invasive Scedosporium spp. and Lomentospora prolificans infection reported in the literature and FungiScope®. *Crit Rev Microbiol.* 2019;45(1):1-21.
282. Troke P, Aguirrebengoa K, Arteaga C, et al. Treatment of scedosporiosis with voriconazole: clinical experience with 107 patients. *Antimicrob Agents Chemother.* 2008;52(5):1743-1750.
283. Jenks JD, Mehta SR, Hoenigl M. Broad spectrum triazoles for invasive mould infections in adults: which drug and when? *Med Mycol.* 2019;57(Suppl\_2):S168-S178.
284. Meletiadis J, Mouton JW, Meis JF, Verweij PE. In vitro drug interaction modeling of combinations of azoles with terbinafine against clinical Scedosporium prolificans isolates. *Antimicrob Agents Chemother.* 2003;47(1):106-117.
285. Howden BP, Slavin MA, Schwarzer AP, Mijch AM. Successful control of disseminated Scedosporium prolificans infection with a combination of voriconazole and terbinafine. *Eur J Clin Microbiol Infect Dis.* 2003;22(2):111-113.
286. Whyte M, Irving H, O'Regan P, Nissen M, Siebert D, Labrom R. Disseminated Scedosporium prolificans infection and survival of a child with acute lymphoblastic leukemia. *Pediatr Infect Dis J.* 2005;24(4):375-377.
287. Bhat SV, Paterson DL, Rinaldi MG, Veldkamp PJ. Scedosporium prolificans brain abscess in a patient with chronic granulomatous disease: successful combination therapy with voriconazole and terbinafine. *Scand J Infect Dis.* 2007;39(1):87-90.
288. Grenouillet F, Botterel F, Crouzet J, et al. Scedosporium prolificans: an emerging pathogen in France? *Med Mycol.* 2009;47(4):343-350.
289. Jenks JD, Reed SL, Seidel D, et al. Rare mould infections caused by Mucorales, Lomentospora prolificans and Fusarium, in San Diego, CA: the role of antifungal combination therapy. *Int J Antimicrob Agents.* 2018;52(5):706-712.
290. Lackner M, Fernandez-Silva F, Guarro J, Lass-Flörl C. Assessing micafungin/triazole combinations for the treatment of invasive scedosporiosis due to Scedosporium apiospermum and Scedosporium boydii. *J Antimicrob Chemother.* 2014;69(11):3027-3032.
291. Rodriguez MM, Calvo E, Serena C, Marine M, Pastor FJ, Guarro J. Effects of double and triple combinations of antifungal drugs in a murine model of disseminated infection by Scedosporium prolificans. *Antimicrob Agents Chemother.* 2009;53(5):2153-2155.
292. Biswas C, Sorrell TC, Djordjevic JT, Zuo X, Jolliffe KA, Chen SC. In vitro activity of miltefosine as a single agent and in combination with voriconazole or posaconazole against uncommon filamentous fungal pathogens. *J Antimicrob Chemother.* 2013;68(12):2842-2846.
293. Kesson AM, Bellemore MC, O'Mara TJ, Ellis DH, Sorrell TC. Scedosporium prolificans osteomyelitis in an immunocompetent child treated with a novel agent, hexadecylphosphocholine (miltefosine), in combination with terbinafine and voriconazole: a case report. *Clin Infect Dis.* 2009;48(9):1257-1261.
294. Bellmann R. Clinical pharmacokinetics of systemically administered antimycotics. *Curr Clin Pharmacol.* 2007;2(1):37-58.
295. Vermes A, Guchelaar HJ, Dankert J. Flucytosine: a review of its pharmacology, clinical indications, pharmacokinetics, toxicity and drug interactions. *J Antimicrob Chemother.* 2000;46(2):171-179.
296. Ashbee HR, Barnes RA, Johnson EM, Richardson MD, Gorton R, Hope WW. Therapeutic drug monitoring (TDM) of antifungal agents: guidelines from the British Society for Medical Mycology. *J Antimicrob Chemother.* 2014;69(5):1162-1176.
297. Hope WW, Billaud EM, Lestner J, Denning DW. Therapeutic drug monitoring for triazoles. *Curr Opin Infect Dis.* 2008;21(6):580-586.
298. Pasqualotto AC, Xavier MO, Andreolla HF, Linden R. Voriconazole therapeutic drug monitoring: focus on safety. *Expert Opin Drug Saf.* 2010;9(1):125-137.
299. Troke PF, Hockey HP, Hope WW. Observational study of the clinical efficacy of voriconazole and its relationship to plasma concentrations in patients. *Antimicrob Agents Chemother.* 2011;55(10):4782-4788.
300. Bruggemann RJ, Blijlevens NM, Burger DM, Franke B, Troke PF, Donnelly JP. Pharmacokinetics and safety of 14 days intravenous voriconazole in allogeneic haematopoietic stem cell transplant recipients. *J Antimicrob Chemother.* 2010;65(1):107-113.
301. Kim Y, Rhee SJ, Park WB, Yu KS, Jang IJ, Lee S. A personalized CYP2C19 phenotype-guided dosing regimen of voriconazole using a population pharmacokinetic analysis. *J Clin Med.* 2019;8(2):1-14.
302. Guinea J, Escribano P, Marcos-Zambrano LJ, et al. Therapeutic drug monitoring of voriconazole helps to decrease the percentage of patients with off-target trough serum levels. *Med Mycol.* 2016;54(4):353-360.
303. Park WB, Kim NH, Kim KH, et al. The effect of therapeutic drug monitoring on safety and efficacy of voriconazole in invasive fungal infections: a randomized controlled trial. *Clin Infect Dis.* 2012;55(8):1080-1087.
304. Ullmann AJ, Cornely OA, Burchardt A, et al. Pharmacokinetics, safety, and efficacy of posaconazole in patients with persistent febrile neutropenia or refractory invasive fungal infection. *Antimicrob Agents Chemother.* 2006;50(2):658-666.
305. Sime FB, Byrne CJ, Parker S, et al. Population pharmacokinetics of total and unbound concentrations of intravenous posaconazole in adult critically ill patients. *Crit Care.* 2019;23(1):205.
306. Vehreschild JJ, Muller C, Farowski F, et al. Factors influencing the pharmacokinetics of prophylactic posaconazole oral suspension in patients with acute myeloid leukemia or myelodysplastic syndrome. *Eur J Clin Pharmacol.* 2012;68(6):987-995.
307. Cattaneo C, Panzali A, Passi A, et al. Serum posaconazole levels during acute myeloid leukaemia induction therapy: correlations with breakthrough invasive fungal infections. *Mycoses.* 2015;58(6):362-367.
308. Pham AN, Bubalo JS, Lewis JS. Comparison of posaconazole serum concentrations from haematological cancer patients on posaconazole tablet and oral suspension for treatment and prevention of invasive fungal infections. *Mycoses.* 2016;59(4):226-233.
309. Chin A, Pergam SA, Fredricks DN, Hoofnagle AN, Baker KK, Jain R. Evaluation of posaconazole serum concentrations from

- delayed-release tablets in patients at high risk for fungal infections. *Antimicrob Agents Chemother.* 2017;61(10):1-8.
310. Tang LA, Marini BL, Benitez L, et al. Risk factors for subtherapeutic levels of posaconazole tablet. *J Antimicrob Chemother.* 2017;72(10):2902-2905.
  311. Desai A, Kovanda L, Kowalski D, Lu Q, Townsend R, Bonate PL. Population pharmacokinetics of isavuconazole from phase 1 and phase 3 (SECURE) trials in adults and target attainment in patients with invasive infections due to *Aspergillus* and other filamentous fungi. *Antimicrob Agents Chemother.* 2016;60(9):5483-5491.
  312. Kovanda LL, Desai AV, Lu Q, et al. Isavuconazole population pharmacokinetic analysis using nonparametric estimation in patients with invasive fungal disease (results from the VITAL study). *Antimicrob Agents Chemother.* 2016;60(8):4568-4576.
  313. Furfaro E, Signori A, di Grazia C, et al. Serial monitoring of isavuconazole blood levels during prolonged antifungal therapy. *J Antimicrob Chemother.* 2019;74(8):2341-2346.
  314. Caillot D, Mannone L, Cuisenier B, Couaillier JF. Role of early diagnosis and aggressive surgery in the management of invasive pulmonary aspergillosis in neutropenic patients. *Clin Microbiol Infect.* 2001;7(Suppl 2):54-61.
  315. Cheng GS, Stednick ZJ, Madtes DK, Boeckh M, McDonald GB, Pergam SA. Decline in the use of surgical biopsy for diagnosis of pulmonary disease in hematopoietic cell transplantation recipients in an era of improved diagnostics and empirical therapy. *Biol Blood Marrow Transplant.* 2016;22(12):2243-2249.
  316. Gossot D, Validire P, Vaillancourt R, et al. Full thoracoscopic approach for surgical management of invasive pulmonary aspergillosis. *Ann Thorac Surg.* 2002;73(1):240-244.
  317. Matt P, Bernet F, Habicht J, et al. Predicting outcome after lung resection for invasive pulmonary aspergillosis in patients with neutropenia. *Chest.* 2004;126(6):1783-1788.
  318. Nosari A, Ravini M, Cairoli R, et al. Surgical resection of persistent pulmonary fungus nodules and secondary prophylaxis are effective in preventing fungal relapse in patients receiving chemotherapy or bone marrow transplantation for leukemia. *Bone Marrow Transplant.* 2007;39(10):631-635.
  319. Theodore S, Liava'a M, Antippa P, et al. Surgical management of invasive pulmonary fungal infection in hematology patients. *Ann Thorac Surg.* 2009;87(5):1532-1538.
  320. Yamamichi T, Horio H, Asakawa A, Okui M, Harada M. Surgery for pulmonary fungal infections complicating hematological malignancies. *Korean J Thorac Cardiovasc Surg.* 2018;51(5):350-355.
  321. de Vega SB, López Ramos I, Ortiz de Lejarazu R, Disdier Vicente C. Fungal Empyema: An Uncommon Entity With High Mortality. *Arch Bronconeumol.* 2017;53(11):641-642.
  322. Kravitz JN, Berry MW, Schabel SI, Judson MA. A modern series of percutaneous intracavitary instillation of amphotericin B for the treatment of severe hemoptysis from pulmonary aspergilloma. *Chest.* 2013;143(5):1414-1421.
  323. Almuhareb A, Habib Z. Management of *Aspergillus* pleural empyema with combined systemic and intrapleural antifungal therapy in a pediatric patient: Case report. *J Infect Public Health.* 2018;11(2):280-282.
  324. Ashizawa N, Nakamura S, Ide S, et al. Successful treatment of aspergillus empyema using open window thoracostomy salvage treatment and the local administration of an antifungal agent. *Intern Med.* 2016;55(15):2093-2099.
  325. Mohan A, Tiwari P, Madan K, et al. Intrabronchial voriconazole is a safe and effective measure for hemoptysis control in pulmonary aspergilloma. *J Bronchology Interv Pulmonol.* 2017;24(1):29-34.
  326. Prasad BPK, Ray B. Singular observation of a desirable change after bronchial artery embolization for hemoptysis in intracavitary aspergilloma. *Indian J Radiol Imaging.* 2017;27(2):225-228.
  327. Schulze M, Vogel W, Spira D, Sauter A, Hetzel J, Horger M. Reduced perfusion in pulmonary infiltrates of high-risk hematologic patients is a possible discriminator of pulmonary angioinvasive mycosis: a pilot volume perfusion computed tomography (VPCT) study. *Acad Radiol.* 2012;19(7):842-850.
  328. Aapro MS, Bohlius J, Cameron DA, et al. 2010 update of EORTC guidelines for the use of granulocyte-colony stimulating factor to reduce the incidence of chemotherapy-induced febrile neutropenia in adult patients with lymphoproliferative disorders and solid tumours. *Eur J Cancer.* 2011;47(1):8-32.
  329. Perruccio K, Tosti A, Burchielli E, et al. Transferring functional immune responses to pathogens after haploidentical hematopoietic transplantation. *Blood.* 2005;106(13):4397-4406.
  330. Vehreschild JJ, Bohme A, Cornely OA, et al. Prophylaxis of infectious complications with colony-stimulating factors in adult cancer patients undergoing chemotherapy-evidence-based guidelines from the Infectious Diseases Working Party AGIHO of the German Society for Haematology and Medical Oncology (DGHO). *Ann Oncol.* 2014;25(9):1709-1718.
  331. Price TH, Boeckh M, Harrison RW, et al. Efficacy of transfusion with granulocytes from G-CSF/dexamethasone-treated donors in neutropenic patients with infection. *Blood.* 2015;126(18):2153-2161.
  332. Hubel K, Carter RA, Liles WC, et al. Granulocyte transfusion therapy for infections in candidates and recipients of HPC transplantation: a comparative analysis of feasibility and outcome for community donors versus related donors. *Transfusion.* 2002;42(11):1414-1421.
  333. Safdar A, Hanna HA, Boktour M, et al. Impact of high-dose granulocyte transfusions in patients with cancer with candidemia: retrospective case-control analysis of 491 episodes of *Candida* species bloodstream infections. *Cancer.* 2004;101(12):2859-2865.
  334. Mousset S, Hermann S, Klein SA, et al. Prophylactic and interventional granulocyte transfusions in patients with hematological malignancies and life-threatening infections during neutropenia. *Ann Hematol.* 2005;84(11):734-741.
  335. Seidel MG, Peters C, Wacker A, et al. Randomized phase III study of granulocyte transfusions in neutropenic patients. *Bone Marrow Transplant.* 2008;42(10):679-684.
  336. Dale DC, Price TH. Granulocyte transfusion therapy: a new era? *Curr Opin Hematol.* 2009;16(1):1-2.
  337. Martino R, Cortes M, Subira M, Parody R, Moreno E, Sierra J. Efficacy and toxicity of intermediate-dose amphotericin B lipid complex as a primary or salvage treatment of fungal infections in patients with hematological malignancies. *Leuk Lymphoma.* 2005;46(10):1429-1435.
  338. Walsh TJ, Finberg RW, Arndt C, et al. Liposomal amphotericin B for empirical therapy in patients with persistent fever and neutropenia. National Institute of Allergy and Infectious Diseases Mycoses Study Group. *N Engl J Med.* 1999;340(10):764-771.
  339. Kontoyiannis DP, Hachem R, Lewis RE, et al. Efficacy and toxicity of caspofungin in combination with liposomal amphotericin B as primary or salvage treatment of invasive aspergillosis in patients with hematologic malignancies. *Cancer.* 2003;98(2):292-299.
  340. Panackal AA, Parisini E, Proschan M. Salvage combination antifungal therapy for acute invasive aspergillosis may improve outcomes: a systematic review and meta-analysis. *Int J Infect Dis.* 2014;28:80-94.
  341. Cornely OA, Meems L, Herbrecht R, Viscoli C, van Amsterdam RG, Ruhnke M. Randomised, multicentre trial of micafungin vs. an institutional standard regimen for salvage treatment of invasive aspergillosis. *Mycoses.* 2015;58(1):58-64.
  342. Kett DH, Shorr AF, Reboli AC, Reisman AL, Biswas P, Schlamm HT. Anidulafungin compared with fluconazole in severely ill patients with candidemia and other forms of invasive candidiasis: support

- for the 2009 IDSA treatment guidelines for candidiasis. *Crit Care*. 2011;15(5):R253.
343. Pagano L, Mele L, Fianchi L, et al. Chronic disseminated candidiasis in patients with hematologic malignancies. Clinical features and outcome of 29 episodes. *Haematologica*. 2002;87(5):535-541.
  344. Queiroz-Telles F, Berezin E, Leverger G, et al. Micafungin versus liposomal amphotericin B for pediatric patients with invasive candidiasis: substudy of a randomized double-blind trial. *Pediatr Infect Dis J*. 2008;27(9):820-826.
  345. Cornely OA, astuey-Izquierdo A, Arenz D, et al. Global guideline for the diagnosis and management of mucormycosis: an initiative of the European Confederation of Medical Mycology in cooperation with the Mycoses Study Group Education and Research Consortium. *Lancet Infect Dis*. 2019;19(12):e405-e421.
  346. Skiada A, Pagano L, Groll A, et al. Zygomycosis in Europe: analysis of 230 cases accrued by the registry of the European Confederation of Medical Mycology (ECMM) Working Group on Zygomycosis between 2005 and 2007. *Clin Microbiol Infect*. 2011;17(12):1859-1867.
  347. Lanterrier F, Dannaoui E, Morizot G, et al. A global analysis of mucormycosis in France: the RetroZygo Study (2005–2007). *Clin Infect Dis*. 2012;54(Suppl 1):S35-S43.
  348. Larkin JA, Montero JA. Efficacy and safety of amphotericin B lipid complex for zygomycosis. *Infections in Medicine*. 2003;20(4):201-206.
  349. Spellberg B, Ibrahim AS, Chin-Hong PV, et al. The Deferasirox-AmBisome Therapy for Mucormycosis (DEFEAT Mucor) study: a randomized, double-blinded, placebo-controlled trial. *J Antimicrob Chemother*. 2012;67(3):715-722.
  350. Brouwer AE, Rajanuwong A, Chierakul W, et al. Combination antifungal therapies for HIV-associated cryptococcal meningitis: a randomised trial. *Lancet*. 2004;363(9423):1764-1767.
  351. Bicanic T, Wood R, Meintjes G, et al. High-dose amphotericin B with flucytosine for the treatment of cryptococcal meningitis in HIV-infected patients: a randomized trial. *Clin Infect Dis*. 2008;47(1):123-130.
  352. Coker RJ, Viviani M, Gazzard BG, et al. Treatment of cryptococcosis with liposomal amphotericin B (AmBisome) in 23 patients with AIDS. *AIDS*. 1993;7(6):829-835.
  353. Sharkey PK, Graybill JR, Johnson ES, et al. Amphotericin B lipid complex compared with amphotericin B in the treatment of cryptococcal meningitis in patients with AIDS. *Clin Infect Dis*. 1996;22(2):315-321.
  354. Jadhav MP, Bamba A, Shinde VM, et al. Liposomal amphotericin B (Fungisome) for the treatment of cryptococcal meningitis in HIV/AIDS patients in India: a multicentric, randomized controlled trial. *J Postgrad Med*. 2010;56(2):71-75.
  355. Jadhav M, Jadhav P, Shinde V, Kadam P, Kshirsagar N. Liposomal amphotericin B for the treatment of cryptococcal meningitis in HIV/AIDS patients in India—a pilot pharmacokinetic study. *Clin Pharmacol Drug Dev*. 2013;2(1):48-52.
  356. Campbell JI, Kanters S, Bennett JE, et al. Comparative effectiveness of induction therapy for human immunodeficiency virus-associated cryptococcal meningitis: a network meta-analysis. *Open Forum Infect Dis*. 2015;2(1):ofv010.
  357. Sun HY, Alexander BD, Lortholary O, et al. Lipid formulations of amphotericin B significantly improve outcome in solid organ transplant recipients with central nervous system cryptococcosis. *Clin Infect Dis*. 2009.
  358. Bandettini R, Castagnola E, Calvillo M, et al. Voriconazole for cryptococcal meningitis in children with leukemia or receiving allogeneic hemopoietic stem cell transplant. *J Chemother*. 2009;21(1):108-109.
  359. Yao Y, Zhang JT, Yan B, et al. Voriconazole: a novel treatment option for cryptococcal meningitis. *Infect Dis (Lond)*. 2015;47(10):694-700.
  360. Li SS, Tang XY, Zhang SG, Ni SL, Yang NB, Lu MQ. Voriconazole combined with low-dose amphotericin B liposome for treatment of cryptococcal meningitis. *Infect Dis (Lond)*. 2016;48(7):563-565.
  361. Nussbaum JC, Jackson A, Namarika D, et al. Combination flucytosine and high-dose fluconazole compared with fluconazole monotherapy for the treatment of cryptococcal meningitis: a randomized trial in Malawi. *Clin Infect Dis*. 2010;50(3):338-344.
  362. Rothe C, Sloan DJ, Goodson P, et al. A prospective longitudinal study of the clinical outcomes from cryptococcal meningitis following treatment induction with 800 mg oral fluconazole in Blantyre, Malawi. *PLoS ONE*. 2013;8(6):e67311.
  363. Gaskell KM, Rothe C, Gnanadurai R, et al. A prospective study of mortality from cryptococcal meningitis following treatment induction with 1200 mg oral fluconazole in Blantyre, Malawi. *PLoS ONE*. 2014;9(11):e110285.
  364. Rolfes MA, Hullsiek KH, Rhein J, et al. The effect of therapeutic lumbar punctures on acute mortality from cryptococcal meningitis. *Clin Infect Dis*. 2014;59(11):1607-1614.
  365. Spec A, Olsen MA, Raval K, Powderly WG. Impact of infectious diseases consultation on mortality of cryptococcal infection in patients without HIV. *Clin Infect Dis*. 2017;64(5):558-564.
  366. Rhein J, Huppler HK, Tugume L, et al. Adjunctive sertraline for HIV-associated cryptococcal meningitis: a randomised, placebo-controlled, double-blind phase 3 trial. *Lancet Infect Dis*. 2019;19(8):843-851.
  367. Sun HY, Alexander BD, Huprikar S, et al. Predictors of immune reconstitution syndrome in organ transplant recipients with cryptococcosis: implications for the management of immunosuppression. *Clin Infect Dis*. 2015;60(1):36-44.
  368. Beardsley J, Wolbers M, Kibengo FM, et al. Adjunctive dexamethasone in HIV-associated cryptococcal meningitis. *N Engl J Med*. 2016;374(6):542-554.
  369. Rybak JM, Marx KR, Nishimoto AT, Rogers PD. Isavuconazole: Pharmacology, pharmacodynamics, and current clinical experience with a new triazole antifungal agent. *Pharmacotherapy*. 2015;35(11):1037-1051.

**How to cite this article:** Ruhnke M, Cornely OA, Schmidt-Hieber M, et al. Treatment of invasive fungal diseases in cancer patients—Revised 2019 Recommendations of the Infectious Diseases Working Party (AGIHO) of the German Society of Hematology and Oncology (DGHO). *Mycoses*. 2020;63:653–682. <https://doi.org/10.1111/myc.13082>